

*Care of the Patient with*  
**Diabetes Mellitus**



**OPTOMETRY:  
THE PRIMARY EYE CARE PROFESSION**

Doctors of optometry (ODs) are the primary health care professionals for the eye. Optometrists examine, diagnose, treat, and manage diseases, injuries, and disorders of the visual system, the eye, and associated structures as well as identify related systemic conditions affecting the eye.

Optometrists provide more than two-thirds of the primary eye care services in the United States. They are more widely distributed geographically than other eye care providers and are readily accessible for the delivery of eye and vision care services. Approximately 37,000 full-time-equivalent doctors of optometry practice in more than 7,000 communities across the United States, serving as the sole primary eye care providers in more than 4,300 communities.

The mission of the profession of optometry is to fulfill the vision and eye care needs of the public through clinical care, research, and education, all of which enhance the quality of life.



**OPTOMETRIC CLINICAL PRACTICE GUIDELINE  
CARE OF THE PATIENT WITH DIABETES MELLITUS  
Reference Guide for Clinicians**

Edited and revised by:

Jerry Cavallerano, O.D., Ph.D. (1<sup>st</sup>, 2<sup>nd</sup>, and 3<sup>rd</sup> Editions)

Reviewed by the AOA Clinical Guidelines Coordinating Committee:

David A. Heath, O.D., Chair  
John F. Amos, O.D., M.S.  
Stephen C. Miller, O.D.

Approved by the AOA Board of Trustees:  
June 22, 2009

©American Optometric Association 2009

The 1st edition was prepared by (and 2nd and 3rd editions reviewed by)  
the American Optometric Association Consensus Panel on Diabetes:  
Larry Alexander, O.D., Chair; Allen Blume, O.D.; Jerry Cavallerano, O.D.,  
Ph.D.; Brian Den Beste, O.D.; Jerry Pederson, O.D.; Lesley L. Walls, O.D.,  
M.D. (1<sup>st</sup>, 2<sup>nd</sup>)  
in conjunction with the Center for Vision Care Policy of the State College of  
Optometry, State University of New York: Barry Barresi, O.D., Ph.D.; Mort  
Soroka, M.P.A., Ph.D.; Gary Oliver, O.D.; Claudia A. Perry, M.L.S.; Leonard  
Werner, O.D.

Edited and revised by: Jerry Cavallerano, O.D., Ph.D. (1<sup>st</sup>, 2<sup>nd</sup>, 3<sup>rd</sup>);  
Ramachandiran Cooppan, M.D. (1<sup>st</sup>, 2<sup>nd</sup>, 3<sup>rd</sup>); Sven-Eric Bursell, Ph.D. (1<sup>st</sup>)  
Reviewed by the AOA Clinical Guidelines Coordinating Committee: John C.  
Townsend, O.D., Chair (3<sup>rd</sup>); John F. Amos, O.D., M.S. (1<sup>st</sup>, 2<sup>nd</sup>, 3<sup>rd</sup>); Kerry L.  
Beebe, O.D. (1<sup>st</sup>); Jerry Cavallerano, O.D., Ph.D. (1<sup>st</sup>); John W. Lahr, O.D. (1<sup>st</sup>);  
Thomas L. Lewis, O.D., Ph.D. (2<sup>nd</sup>); W. Howard McAlister, O.D., M.P.H. (3<sup>rd</sup>);  
Stephen C. Miller, O.D. (2<sup>nd</sup>, 3<sup>rd</sup>) Michael W. Rouse, O.D. (2<sup>nd</sup>); Richard L.  
Wallingford, O.D. (1<sup>st</sup>)

Approved by the AOA Board of Trustees June 23, 1993 (1<sup>st</sup>), September 10,  
1998 (2nd), and August 17, 2002 (3rd)

©American Optometric Association 1993, 1998, 2002  
243 N. Lindbergh Blvd., St. Louis, MO 63141-7881  
Printed in U.S.A.

NOTE: Clinicians should not rely on the Clinical  
Guideline alone for patient care and management.  
Refer to the listed references and other sources  
for a more detailed analysis and discussion of  
research and patient care information. The  
information in the Guideline is current as of the  
date of publication. It will be reviewed periodically

**TABLE OF CONTENTS**

**INTRODUCTION** ..... 1

**I. STATEMENT OF THE PROBLEM** ..... 2

A. Description and Classification of Diabetes Mellitus ..... 3

1. Diabetes Mellitus ..... 3

    a. Type 1 Diabetes Mellitus ..... 4

    b. Type 2 Diabetes Mellitus ..... 5

    c. Impaired Glucose Tolerance ..... 6

    d. Gestational Diabetes Mellitus ..... 6

    e. Other Specific Types of Diabetes ..... 7

2. Treatment of Diabetes Mellitus ..... 7

B. Epidemiology of Diabetes Mellitus ..... 13

1. Prevalence and Incidence ..... 13

    a. Diabetes Mellitus ..... 13

    b. Ocular Manifestations ..... 13

2. Risk Factors ..... 15

    a. Screening for Diabetes Mellitus ..... 15

    b. Examination for Ocular Manifestations of Diabetes Mellitus ..... 16

C. Clinical Background of Ocular Manifestations of Diabetes Mellitus ..... 16

1. Natural History ..... 16

2. Classification and Signs of Diabetic Retinopathy ..... 20

    a. Nonproliferative Diabetic Retinopathy ..... 20

    b. Proliferative Diabetic Retinopathy ..... 21

    c. Macular Edema ..... 22

3. International Classification of DR ..... 22

4. Early Detection and Prevention ..... 23

**II. CARE PROCESS** ..... 25

A. Diagnosis of Ocular Manifestations of Diabetes Mellitus ..... 25

1. Patient History ..... 25

    a. Patients with Undiagnosed Diabetes Mellitus ..... 25

    b. Patients with Diagnosed Diabetes Mellitus ..... 26

2. Ocular Examination ..... 28

3. Examination Technique ..... 28

4. Supplemental Testing ..... 29

B. Management of Ocular Manifestations of Diabetes Mellitus ..... 30

1. Basis for Treatment ..... 30

    a. Patients with Undiagnosed Diabetes Mellitus ..... 30

    b. Patients with Nonretinal Ocular Complications ..... 30

    c. Patients with Retinal Complications ..... 31

2. Available Treatment Options ..... 37

    a. Nonproliferative Diabetic Retinopathy ..... 37

    b. Proliferative Diabetic Retinopathy ..... 38

    c. Macular Edema ..... 39

3. Patient Education ..... 40

4. Prognosis and Followup ..... 42

5. Management of Patients with Severe, Irreversible Vision Loss ..... 43

**CONCLUSION** ..... 45

**II. REFERENCES** ..... 46

**III. APPENDIX** ..... 62

Figure 1: Optometric Management of the Patient with Undiagnosed Diabetes Mellitus: A Brief Flowchart ..... 62



Figure 2: Optometric Management of the Patient with Diagnosed Diabetes Mellitus: A Brief Flowchart ..... 63

Figure 3: Frequency and Composition of Evaluation and Management Visits for Retinal Complications of Diabetes Mellitus ..... 64

Figure 4: ICD-9-CM Classification of Ocular Complications of Diabetes Mellitus ..... 66

Abbreviations of Commonly Used Terms ..... 69

Glossary ..... 72



## **INTRODUCTION**

Optometrists, through their clinical education, training, experience, and broad geographic distribution, have the means to provide primary eye and vision care for the American public. They are often the first health care practitioners to examine patients with undiagnosed diabetes mellitus (DM) or ocular manifestations of DM.

This Optometric Clinical Practice Guideline for the Care of the Patient with Diabetes Mellitus provides optometrists examination and management recommendations to preserve vision and to reduce the risks of vision loss in patients with DM through timely diagnosis and appropriate referral and intervention.

This Guideline will assist optometrists in achieving the following goals:

- Identify patients with undiagnosed DM
- Identify patients at risk for vision loss from DM
- Preserve human vision by reducing the risk of vision loss in patients with DM through timely diagnosis, intervention, determination of need for future evaluation, and appropriate referral
- Improve the quality of care rendered to patients with DM
- Disseminate information and continue the education of health care practitioners regarding the ocular complications of DM and the availability of vision rehabilitation programs
- Stress availability of vision rehabilitation for those with vision loss from DM through low vision devices and psychosocial support.

## **I. STATEMENT OF THE PROBLEM**

Diabetes mellitus (DM) is a chronic disease with long-term macrovascular and microvascular complications, including diabetic nephropathy, neuropathy, and retinopathy. It is a leading cause of death, disability, and blindness in the United States for persons 20–74 years of age.<sup>1-3</sup> Approximately 80 percent of blindness in this age group is related to diabetic retinopathy (DR). At least 50,000 Americans are legally blind from this condition. Diabetes is also responsible for 5,800, or 10 percent, of the new cases of blindness reported annually.<sup>4</sup>

Although DR is not preventable or curable, many patients can avoid vision loss or blindness because of advances in the management of diabetes and DR.<sup>5</sup> Early diagnosis, intensive treatment, and consistent, long-term followup evaluations for diabetic patients are essential for effective care, which can help preserve vision and significantly lower the risk of blindness. Clinical research has shown that intensive treatment to maintain blood glucose concentrations close to the normal range can decrease the risk of developing DR by 76 percent in patients with type 1 diabetes.<sup>6</sup>

Approximately 26 percent of patients with type 1 DM and 36 percent with type 2 DM have never had their eyes examined.<sup>7</sup> These patients tend to be older, less educated, and more recently diagnosed than those receiving regular eye care.<sup>7</sup> They also are likely to live in rural areas and to receive their health care from a family physician or general practitioner.<sup>7</sup> Furthermore, 32 percent of patients with DM who are at high risk for vision loss have never received an eye examination.<sup>8</sup> When examined, almost 61 percent of these patients exhibit DR, cataract, glaucoma, or other ocular manifestations of DM. These findings are particularly disturbing because the Diabetic Retinopathy Study (DRS),<sup>9-21</sup> Early Treatment Diabetic Retinopathy Study (ETDRS),<sup>22-44</sup> and Diabetic Retinopathy Vitrectomy Study (DRVS)<sup>45-49</sup> demonstrated that early referral for eye care and prompt and appropriate intervention lessen the risk for and the severity of vision loss related to diabetes. Early referral is crucial for African American and Hispanic patients; 37.3 percent of African American patients and 42.9 percent of Hispanic patients have significant DR at the initial diagnosis of DM.<sup>50</sup>

**A. Description and Classification of Diabetes Mellitus**

**1. Diabetes Mellitus**

Diabetes mellitus (DM) is a group of metabolic diseases characterized by hyperglycemia resulting from defects of insulin secretion and/or increased cellular resistance to insulin. Chronic hyperglycemia and other metabolic disturbances of DM lead to long-term tissue and organ damage as well as dysfunction involving the eyes, kidneys, and nervous and vascular systems.<sup>51-53</sup> The definitions and categories of DM used in this document are based on the most recent classifications reported by the American Diabetes Association.<sup>52,54,55</sup> (See Appendix Figure 4 for ICD-9-CM classifications).

The classification of DM has undergone the following important changes:<sup>52</sup>

1. The designations “type 1 diabetes” and “type 2 diabetes,” using Arabic numerals, replace the terms "insulin dependent diabetes mellitus" (IDDM) and "non-insulin dependent diabetes mellitus" (NIDDM).
2. A new term, "IFG" (impaired fasting glucose), defines glucose values that are greater than or equal to 100 mg/dl and up to 125 mg/dl.
3. The revised diagnostic criteria for DM are:
  - a. A1C level  $\geq 6.5\%$ . Diagnosis should be confirmed with repeat A1C test unless clinical symptoms and glucose levels  $\geq 200$  mg/dl are present. (Prior criteria should be used in the absence of A1C testing.)<sup>56</sup>
  - b. Symptoms of hyperglycemia plus casual plasma glucose concentration greater than or equal to 200 mg/dl. "Casual" is defined as any time of the day without regard to time since the last meal. Classic symptoms of hyperglycemia include

**4 Diabetes Mellitus**

polyuria, polydipsia, and unexplained weight loss.

OR

- c. Fasting plasma glucose greater than or equal to 126 mg/dl. "Fasting" means no caloric intake for at least 8 hours. A test yielding an abnormal result must be repeated on a different day.



OR

- d. Two-hour plasma glucose greater than or equal to 200 mg/dl during an oral glucose tolerance test (OGTT), using a 75-g glucose challenge, as described by the World Health Organization (WHO).<sup>55</sup>

**a. Type 1 Diabetes Mellitus**

The American Diabetes Association provides clear definitions of the various types of diabetes and classification, diagnosis, and clinical care of diabetes. Type 1 DM, which results from destruction of beta cells in the pancreas, accounts for approximately 10 percent of all patients with DM in the United States. It leads to absolute insulin deficiency. There are two forms of type 1 DM. One is an immune-mediated disease with autoimmune markers such as islet cell antibodies (ICAs), insulin autoantibodies (IAAs), and autoantibodies to glutamic acid decarboxylase (GAD65). As many as 85–90 percent of patients with fasting hyperglycemia are positive for one or more of these markers. Strong human leukocyte antigen (HLA) associations also exist. A second form of type 1 DM, now called idiopathic diabetes, has no known cause. Only a minority of patients fall into this group, which occurs mainly in individuals of African and Asian origin. Idiopathic diabetes is strongly heritable, but it lacks autoimmune markers and is not HLA-associated.

Although it can occur at any age, type 1 DM is more common in persons less than 30 years of age. The rate of pancreatic destruction is variable and is generally more rapid in infants and children and slower in adults.



Patients tend to be acutely symptomatic at onset, often complaining of polydipsia, polyphagia, polyuria, unexplained weight loss, dry mouth, pruritus, leg cramps or pains, delayed healing of skin wounds, and recurrent infections of the skin, genitalia, or urinary tract. The primary characteristic of type 1 DM is absolute dependence on exogenous insulin to prevent ketoacidosis.

**b. Type 2 Diabetes Mellitus**

Type 2 is the most common form of DM worldwide, and its prevalence is increasing. Its underlying defects can vary from predominant insulin resistance with relative insulin deficiency to a predominant insulin-secretory defect with insulin resistance. A great deal of heterogeneity exists, and most patients with type 2 DM do not initially require insulin therapy.

Accounting for approximately 90 percent of all cases of DM in the United States, type 2 DM occurs more frequently in adults than in children, and the incidence increases with age, especially after age 40. However, the prevalence of type 2 DM in children is increasing, especially in the high-risk ethnic groups, such as Native Americans, Hispanic Americans, African Americans, and Asian Americans. Most of these children are between 10 and 19 years old, have had symptoms longer, have infrequent or mild diabetic ketoacidosis, are obese, and have a strong family history of diabetes. A characteristic finding is darkening of the skin (acanthosis nigricans) and there is an increased incidence of insulin resistance.<sup>57,58</sup>

Because the onset is frequently insidious, many patients with type 2 DM are asymptomatic and remain undiagnosed for years. Upper body obesity is a recognized risk factor because it results in peripheral insulin resistance. The beta cells compensate for this resistance by increasing insulin secretion and maintaining normal glucose tolerance. Eventually, the hyperglycemia worsens, glucose toxicity ensues, and insulin secretion and action decrease. Ultimately, the loss of beta cell mass can lead to insulin dependency. The expanded definition of the insulin resistance syndrome now includes glucose intolerance, hypertension, dyslipidemia (high triglycerides, low HDL cholesterol, and increased

LDL), increased plasminogen activator inhibitor (PAI-1) levels, reduced sex-binding globulin, coronary artery disease, and diffuse atherosclerosis. These findings may be the basis for the marked increase in coronary heart disease reported in type 2 DM.

**c. Impaired Fasting Glucose and Impaired Glucose Tolerance**

Patients with hyperglycemia at levels that are below the diagnostic criteria for DM are diagnosed with impaired fasting glucose (IFG) or impaired glucose tolerance (IGT), depending on the test used: IFG, by the fasting plasma glucose (FPG) test; IGT, by the oral glucose tolerance test (OGTT). In IFG, the fasting glucose levels are greater than or equal to 100 mg/dl and up to 125 mg/dl; for IGT, the 2-hour plasma glucose value is greater than or equal to 140 mg/dl and up to 199 mg/dl. Most individuals with IFG and IGT are euglycemic in daily life and often have normal glycosylated hemoglobin (HbA1C) levels.<sup>52</sup>

Both IFG and IGT are risk factors for future DM. Serial testing shows that such patients may improve, remain stable, or worsen. Neither IFG nor IGT is associated with the microvascular complications of DM, but they have been linked with macrovascular disease.

**d. Gestational Diabetes Mellitus**

By definition, gestational diabetes mellitus (GDM) is any degree of glucose intolerance with onset or first diagnosis during pregnancy. Usually diagnosed during the second or third trimester, GDM occurs in approximately 4 percent of pregnancies or 135,000 cases annually. The prevalence rate of 1–14 percent depends upon the population studied. Glucose tolerance usually returns to normal within 6 weeks after pregnancy ends, at which time the woman needs to be reclassified. Most GDM patients do not develop DM later in life, but some will develop IFG, IGT, type 2 DM, or even type 1 DM. Because increased fetal mortality and morbidity have been associated with GDM, prompt detection and aggressive treatment are important. GDM remains a subgroup within the new classification, but the screening criteria have been revised. No longer do all pregnant women require screening; those exempted must meet all of the following criteria<sup>54</sup> (1) less than 25 years



of age, (2) normal weight before pregnancy, (3) member of an ethnic group with low prevalence of DM, (4) no known DM in first-degree relatives, (5) no history of abnormal glucose tolerance, and (6) no history of poor obstetric outcome.

Risk assessment should be conducted early in the pregnancy and glucose testing should be conducted promptly for those with risk characteristics. For women with risk characteristics whose initial screening shows no sign of GDM, followup screening should be performed between 24 and 28 weeks, using an OGTT.<sup>59</sup>

***e. Other Specific Types of Diabetes***

DM can also occur secondary to genetic defects in beta cell function or insulin action, pancreatic diseases or other endocrinopathies, medications, toxic chemicals, or uncommon forms of immune-mediated diabetes, e.g., "stiff man syndrome" or the presence of anti-insulin-receptor antibodies. The defects in beta cell function are better characterized since linkage of chromosome 7 to the glucokinase deficiency found in maturity-onset diabetes of the young (MODY) 2. MODY 3 is linked to chromosome 12 and MODY 1 to chromosome 20.<sup>49</sup> Although few patients have DM related to these other entities, the clinician interpreting blood glucose screening results must consider the patient's medical history.

**2. Treatment of Diabetes Mellitus**

DM treatment comprises one or more of the following modalities: medical nutrition therapy, exercise, insulin, and noninsulin agents, including oral medications and the non-insulin injectable drug exenatide. Every patient with DM should receive dietary recommendations, explained by a dietitian. When used early in the disease process, medical nutritional therapy and weight loss may be sufficient to control type 2 DM in many patients. Dietary recommendations, which take into account the patient's total daily caloric requirements, are designed to promote weight control to achieve an ideal body weight. Optimal carbohydrate, protein, and fat intake levels usually are determined according to ADA guidelines.<sup>60</sup>

Insulin therapy is required for all patients with type 1 DM and for those patients whose type 2 DM is not adequately controlled or is unresponsive to diet and oral medications. The goal of therapy is to maintain normal or near-normal blood glucose levels throughout the day. For type 2 DM, six classes of oral agents are available in the United States.<sup>61</sup>

- Sulfonylurea compounds primarily stimulate the pancreatic islets' secretion of insulin; their use also results in reduction of hepatic glucose production, reversal of the post-receptor defect, and increase in the number of insulin receptors.
- The nonsulfonylurea insulin secretagogues repaglinide and nateglinide bind to a specific site on the sulfonylurea receptor and increase insulin secretion, although they are short-acting agents.
- Biguanides, such as metformin, block hepatic glucose production.
- $\alpha$ -glucosidase inhibitors, such as acarbose and miglitol, block starch, sucrose, and maltose absorption.
- Thiazolidinediones, such as pioglitazone and rosiglitazone, decrease insulin resistance by enhancing insulin-mediated glucose disposal by muscle. Because of idiosyncratic liver damage and liver failure, the Food and Drug Administration (FDA) removed one of the thiazolidinediones, troglitazone, from clinical use in the United States in 2000. Meta-analysis of clinical studies showed rosiglitazone to be associated with an increased risk of myocardial ischemic events such as angina or myocardial infarction; an increase in the risk of death from cardiovascular cause had borderline significance. Other studies comparing rosiglitazone to some other approved oral antidiabetic agents or placebo have not confirmed or excluded this risk. The available data on the risk of myocardial ischemia are inconclusive.<sup>62</sup>
- Among the incretinmimetic agents, sitagliptin is a dipeptidyl peptidase-IV inhibitor that blocks the inactivation of native glucagon-like peptide. Another incretinmimetic, exenatide,

administered by subcutaneous injection twice daily, stimulates insulin secretion, suppresses hyperglucagonemia, delays gastric emptying, and depresses appetite.

The use of combination oral therapies and oral therapies combined with insulin is common and increasing. A combination approach offers the patient the potential benefit from the synergistic actions of different medications while reducing adverse effects. Fixed-dose combinations are now emerging for treatment of type 2 DM. Also available are insulin preparations such as the basal insulin glargine and a rapid-acting insulin, insulin aspart. These advances enable the initiation of more effective basal bolus insulin therapy, which can result in better glycemic control.

The results of the landmark Diabetes Control and Complications Trial (DCCT) have clearly demonstrated that intensive therapy can reduce the long-term complications of type 1 DM.<sup>6,63-67</sup> This clinical trial involved randomly assigning 1,441 type 1 DM patients to intensive insulin therapy or conventional insulin therapy groups and following them for a mean of 6.5 years. The trial's two-arm design enabled study of both primary prevention and secondary intervention for DM. The goal was to keep the glycosylated hemoglobin (HbA1C) levels below 6.05 percent. Intensive therapy in the DCCT reduced the development of DR by 76 percent and the progression of DR by 60 percent; it reduced the risk for nephropathy and neuropathy by 60 percent overall. There was a threefold increase in the rate of hypoglycemia with intensive therapy, but there were no deaths. The mean 7.2 percent HbA1C obtained in the intensive treatment group was 2 percent lower than the 9.1 percent obtained in the conventional therapy group.<sup>68</sup>

Similar in design to the DCCT, the smaller, 110-subject Kumamoto Study in Japan produced similar results using intensive insulin therapy in lean type 2 diabetic patients.<sup>69</sup> The Stockholm Diabetes Intervention Study also noted a strong relationship between glycemic control and microvascular complications.<sup>70</sup>

The landmark United Kingdom Prospective Diabetes Study (UKPDS) results were published in 1998.<sup>71</sup> A total of 3,867 newly diagnosed patients with type 2 DM, randomized to conventional treatment with diet,

to intensive treatment with oral therapy (sulfonylureas or metformin), or to insulin, had been followed for 9 years. At the end of the study, the main difference was in mean HbA1C values: intensive-treatment group, 7.9 percent; conventional treatment group, 9.0 percent. This reduction was associated with a 25 percent overall reduction in diabetic endpoints. Furthermore, the UKPDS showed a reduction in cardiovascular death in a subgroup of obese patients treated with metformin. This study also found that 50 percent of the patients had evidence of some diabetic complication at diagnosis and that all monotherapies lost efficacy with time. The results of this trial further emphasized the need for earlier diagnosis and more aggressive treatment of these patients. Significantly, there is a prolonged benefit of early intensive control of blood glucose levels in patients with type 2 DM, underscoring the importance of early diagnosis.<sup>72</sup> This so-called "legacy effect" demonstrates that despite a loss of difference in HgA1c levels for the intensive and conventional groups, a beneficial effect resulting in reduction of microvascular complications persists up to 10 years later for both the sulfonylurea and metformin groups in the UKPDS.

The Epidemiology of Diabetes Interventions and Complications (EDIC) Study continues to monitor 1,375 of the 1,441 DCCT subjects for DR, renal function, and glycemic control as well as complications. EDIC Study results show that 7 years after the DCCT ended, fewer of the patients who had been on intensive therapy during the DCCT had less DR, despite convergence of HbA1C levels following the conclusion of the DCCT.<sup>68</sup> At the 7-year EDIC followup, the mean HbA1C values for the intensive therapy and conventional therapy groups were 7.9 and 8.2 percent, respectively, compared with mean HbA1C values at the end of the DCCT, 7.2 and 9.1 percent for the intensive therapy and conventional therapy groups, respectively. These HbA1C levels reflect the continuing benefits of early intensive control, regardless of the possibility of subsequent less-intensive control, and they strongly support the rationale for improving glycemic control as early as possible in patients with DM.<sup>73</sup> These studies also showed that there was no glycemic threshold for the development of the microvascular complications, therefore making it important for the clinician to aim for the best control possible without increasing the patient's risks for hypoglycemia. Recent studies show, however, that the benefit of prior intensive diabetes therapy on

retinopathy risk does wane over time, and there is increased benefit of continued intensive control.<sup>74</sup>

Insulin may be administered as conventional twice-daily injections, as multiple pre-meal and bedtime injections, or as continuous subcutaneous insulin pump infusion regimens. The most recent advance in insulin is the use of LYSPRO insulin, a fast-acting recombinant deoxyribonucleic acid (DNA) human insulin that peaks in 15–30 minutes and lasts 2–3 hours, enabling the patient to control postprandial hyperglycemia more effectively. Most patients require some type of multiple or split-dosage regimen to maintain adequate control. The recently introduced insulin analog glargine provides the first true basal insulin. Most patients can use this analog once daily because of the long duration of its action, which has a steady absorption profile that is without peaks. Glargine forms the basal component of a multiple daily insulin regimen that includes rapid-acting pre-meal boluses. Daily self-monitoring of blood glucose by the patient, using a finger-prick sample with a glucose monitor, is a well-accepted practice. Such monitoring, which is absolutely necessary for intensive management programs, is encouraged for all diabetic patients.<sup>75,76</sup>

Appropriate action by the optometrist includes education and referral to a diabetes management team, for direction of the patient's medication changes and glucose self-testing or consultation with an endocrinologist or diabetologist. Table 1 summarizes the American Diabetes Association (ADA) Clinical Practice Recommendations for glucose control of patients with diabetes.<sup>60,75</sup>

**Table 1**  
**Standards for Glucose Control**

<b>Biochemical index</b>	<b>Non-diabetic values</b>	<b>Diabetic goals</b>	<b>Intervention indicated in diabetes</b>
Preprandial glucose	110 mg/dl	80–120 mg/dl	<80 or >140 mg/dl
Bedtime glucose	<120 mg/dl	100–140 mg/dl	<100 or >160 mg/dl
Glycosylated hemoglobin (HbA1C)	<6%	<7%	>8%



**B. Epidemiology of Diabetes Mellitus**

**1. Prevalence and Incidence**

*a. Diabetes Mellitus*

Diabetes mellitus affects an estimated 24 million Americans (8.0%), with approximately 6 million of these American undiagnosed and unaware of their disease.<sup>77</sup> The prevalence of DM, estimated at 10 percent of persons over the age of 60 years, rises to 16–20 percent among those over the age of 80.<sup>78,79</sup> The overall prevalence among adults was 7.4 percent in 1995 and is expected to reach 9 percent in 2025. The annual incidence of type 1 DM in children from birth to 16 years of age varies with ethnicity and is approximately 3–26 new cases per 100,000 persons. For example, among African Americans in San Diego, CA, it is 3.3 per 100,000 and among whites in Rochester, MN, it is 20.6 per 100,000. Approximately 0.3 percent of the population develops the disease by 20 years of age.<sup>80</sup> The annual incidence of type 2 DM is approximately 2.4 per 1,000 persons over age 20. By 65 years of age, 10 percent of the population may have type 2 DM. The prevalence is highest in Native Americans, followed by Hispanics, African Americans, and Asians.<sup>80,81</sup>

*b. Ocular Manifestations*

Diabetic retinopathy (DR) is the leading cause of new blindness in the 20- to 74-year-old population in the United States. It accounts for approximately 12 percent of all new cases of blindness each year. The prevalence of DR among patients with DM depends more on duration of the disease than on the patient's age.<sup>82-84</sup> The actual duration of DM can be difficult to determine because the initial diagnosis may be made after a period of asymptomatic DM, especially in cases of type 2 DM, which has a more gradual onset. The projected ocular manifestations, by type and duration of DM, are summarized in Table 2.

The incidence of all ocular manifestations of DM increases with age and duration of the disease, whether type 1 or type 2. Approximately 5 percent of the population with DM may develop glaucoma, compared

**Table 2**  
**Duration of Diabetes Mellitus and Presence of Eye Disease**

<b>Diabetes</b>	<b>Duration of disease</b>	<b>Ocular Manifestations</b>
Type 1	>10 years	60% have some retinopathy.
	>15 years	Virtually all patients have some degree of retinopathy; 25% progress to proliferative diabetic retinopathy.
	>20 years	50% progress to proliferative retinopathy.
Type 2	At diagnosis	20% have retinopathy
	> 4 years	4% progress to proliferative retinopathy
	>15 years	60%-80% have some retinopathy; up to 20% progress to proliferative retinopathy.

with about 2 percent of the general population.<sup>85</sup> Glaucoma also has a higher prevalence in groups at known risk for DM, including African Americans, Native Americans, and older persons.

Cataracts are 2–4 times more prevalent, occur at younger ages, and progress more rapidly in patients with DM than in the general population.<sup>83</sup> The DCCT showed that strict control of blood glucose can prevent or lessen the severity of ocular complications in persons with type 1 DM.<sup>6,62</sup> The United Kingdom Prospective Diabetes Study showed similar findings for persons with type 2 DM.<sup>70</sup>



## **2. Risk Factors**

### **a. Screening for Diabetes Mellitus**

Because of the high prevalence of type 2 DM and the increased morbidity and mortality associated with the disease, the ADA now recommends diabetes screening for all adults aged 45 years and older.<sup>51,52</sup> For individuals at higher risk, screening should be considered at younger ages and performed more frequently.

The high-risk individual is one who:

- Is obese (>120% desirable body weight or body mass index >25 kg/m<sup>2</sup>) Has a first-degree relative with DM
- Is a member of a high-risk ethnic population (i.e., African American, Hispanic, Native American)
- Has delivered a baby weighing more than 9 pounds or has been diagnosed with GDM
- Is hypertensive (blood pressure >140/90)
- Has an HDL cholesterol level <35 mg/dl and/or a triglyceride level >250 mg/dl
- Has had IGT or IFG on previous testing.

Screening includes an FPG test or a 2-hour OGTT (75-g glucose load) or both. Patients whose results are normal should be checked in 3 years.<sup>51</sup> Patients with positive results should be retested. Screening of urine glucose levels is not recommended.

AUTHORITY OF OPTOMETRISTS TO ORDER LAB AND OTHER DIAGNOSTIC TESTS:  
Unless there is a specific limitation in the optometry Act or other section of state law regarding which diagnostic laboratory, radiology, or other tests an optometrist may order, an optometrist may order those tests rational to the diagnosis or conditions of the eye, adjacent structures, the vision system; or for systemic conditions affecting the eye, - as defined by the applicable standard of care.  
American Optometric Association State Government Relations Center, July 2009

### **b. Examination for Ocular Manifestations of Diabetes Mellitus**

The clinical signs of DR can appear early in the natural history of the disease. Unfortunately, patients may not experience symptoms until relatively late, at which time treatment may be less effective. The success of appropriate intervention and management strategies depends upon accurate and timely detection of diabetic eye disease. The ADA recommends the following eye exam schedule for persons with DM:<sup>85,86</sup>

- Adults and children aged 10 years or older with type 1 DM should have an initial comprehensive, dilated-pupil eye examination within 5 years after the onset of DM.
- The patient with type 2 DM should have an initial comprehensive, dilated-pupil eye examination shortly after the diagnosis of DM.
- Subsequent examinations for type 1 and type 2 DM patients should be repeated annually. Less frequent examination may be considered in the setting of a normal eye exam. More frequent examination is required when DR is progressing.
- Women with pre-existing DM who are planning pregnancy or who has become pregnant should have a comprehensive eye examination and should receive counseling on the risk of development and/or progression of DR. The examination should be done in the first trimester, with close followup throughout the pregnancy and for 1 year post partum.

### **C. Clinical Background of Ocular Manifestations of Diabetes Mellitus**

#### **1. Natural History**

Diabetic eye disease is an end-organ response to a systemic medical condition. All structures of the eye and many aspects of visual function are susceptible to the deleterious effects of DM (Table 3).

DR is the most serious sight-threatening complication of diabetes. The two broad categories of DR are nonproliferative diabetic retinopathy

**Table 3**  
**Ocular and Visual Complications of Diabetes Mellitus**

<b>Functional</b>	Tritan color vision deficiencies Refractive error changes Accommodative dysfunction Visual field defects
<b>Extraocular muscle anomalies</b>	Mononeuropathies involving third, fourth, or sixth cranial nerves
<b>Pupillary reflexes</b>	Sluggish pupillary reflexes
<b>Conjunctiva</b>	Bulbar conjunctival microaneurysms
<b>Tear film</b>	Tear film deficiencies resulting in dry eye syndrome
<b>Cornea</b>	Reduced corneal sensitivity Reduced corneal wound-healing ability Basement membrane abnormalities resulting in increased frequency of abrasions or recurrent erosion syndrome Descemet's membrane wrinkling Endothelial cell morphology changes, often resulting in increased corneal thickness
<b>Iris</b>	Depigmentation Rubeosis iridis, possibly with associated ectropion uvea and peripheral anterior synechiae Neovascular glaucoma
<b>Lens</b>	Higher prevalence of cataracts Reversible opacities and snowflake cataracts rarely seen in industrialized countries)
<b>Vitreous</b>	Hemorrhage in proliferative retinopathy
<b>Retina</b>	Nonproliferative retinopathy Proliferative retinopathy Macular edema
<b>Optic nerve</b>	Papillopathy Ischemic optic neuropathy Higher incidence of open-angle glaucoma

(NPDR) and proliferative diabetic retinopathy (PDR). Moreover, diabetic macular edema (ME) can be present at any level of NPDR or PDR.

Although the pathophysiological processes responsible for the various lesions of DR and maculopathy are not fully understood, various individual retinal lesions indicate the risk for progression of DR and vision loss.<sup>34</sup> Biochemical changes in the retina and alteration in retinal blood flow are early changes resulting from diabetes.<sup>87,88,89</sup> Loss of intramural pericytes, either preceding or secondary to the development of capillary nonperfusion, weakens the retinal capillary walls. The result is saccular outpocketing of these capillaries called microaneurysms (Ma), which are frequently the earliest clinical sign of DR.

Ruptured microaneurysms, leaking capillaries, and intraretinal microvascular abnormalities (IRMA) result in intraretinal hemorrhages. The clinical appearance of these hemorrhages reflects the architecture of the retinal layer in which the hemorrhage occurs. Hemorrhages in the nerve fiber layer of the retina have a flame-shaped appearance and coincide with the structure of the nerve fiber layer that lies parallel to the retinal surface. Hemorrhages deeper in the retina, where the arrangement of cells is more or less perpendicular to the surface of the retina, assume a pinpoint or dot shape and are more characteristic of DR.

Intraretinal microvascular abnormalities represent either new vessel growth within the retina or, more likely, pre-existing vessels with endothelial cell proliferation that serve as "shunts" through areas of nonperfusion. IRMA are frequently adjacent to cotton wool spots. Whereas multiple IRMA mark a severe stage of nonproliferative retinopathy, frank neovascularization is likely to occur on the surface of the retina or optic disc within a short time.

Venous caliber abnormalities are indicators of severe retinal hypoxia. These abnormalities can take the form of venous dilation, venous beading (VB), or loop formation. Large areas of nonperfusion can



appear adjacent to these abnormal veins. VB is a significant risk factor for progression to proliferative retinopathy.

Proliferative DR is marked by the proliferation of endothelial cell tubules. The rate of growth of these new vessels, either at or near the optic disc (neovascularization of the disc, or NVD) or elsewhere in the retina (neovascularization elsewhere, or NVE), varies. Adjacent to the new vessels, translucent fibrous tissue often appears. This fibroglial tissue becomes opaque and begins adhering to the adjacent vitreous.

Although PDR is responsible for the most severe vision loss, macular edema is the most common cause of reduced visual acuity in persons with DM. Diabetes alters the structure of the macula, thereby significantly altering its function, in any of the following ways:<sup>84</sup>

- The collection of intraretinal fluid in the macular portion of the retina, with or without lipid exudates and with or without cystoid changes (macular edema)
- Nonperfusion of parafoveal capillaries, with or without intraretinal fluid
- Traction in the macula by fibrous proliferation, causing dragging of the retinal tissue, surface wrinkling, or detachment of the macula
- Intraretinal or preretinal hemorrhage (PRH) in the macula
- Lamellar or full-thickness hole formation
- Any combination of the above.

Clinically, diabetic ME is hard exudate (HE) or retinal thickening within one disc diameter (DD) of the center of the macula. Retinal thickening or hard exudate with adjacent retinal thickening that threatens or involves the center of the macula is considered "clinically significant macular edema" (CSME).

Diabetic papillopathy and acute optic disc edema having the appearance of pseudopapilledema can reduce vision, particularly in patients with type 1 DM. The papillopathy may present with or without an afferent

pupillary defect or visual field defect.<sup>90</sup> Diabetic papillopathy is a distinct clinical entity that must be distinguished from papilledema or other etiologies of optic disc swelling.<sup>91</sup> Visual acuity is usually moderately reduced, and the prognosis for improvement upon resolution is good. Diffuse microangiopathy may be associated with the etiology of diabetic papillopathy; however, there appears to be no correlation between diabetic papillopathy and either the degree of DR or the level of clinical control of the patient's DM.<sup>90,93</sup>

Patients with DM are at risk for ischemic optic neuropathy, which may occur with or without evidence of DR. Diabetes-related anterior ischemic optic neuropathy usually presents with optic disc pallor, swelling and hemorrhages, sudden decreased vision, an afferent pupillary defect, and an altitudinal visual field defect. The condition often results in optic atrophy and reduced visual acuity.<sup>93</sup> The clinical appearance of early anterior ischemic optic neuropathy is difficult to distinguish from that of diabetic papillopathy.<sup>90</sup> Diabetic patients are also susceptible to retrobulbar ischemic optic neuropathy, although its occurrence is uncommon in DM.

## **2. Classification and Signs of Diabetic Retinopathy**

The two broad categories of DR are nonproliferative diabetic retinopathy and proliferative diabetic retinopathy.

Appendix Figure 4 lists the ICD-9-CM classification of ocular complications of DM.

### **a. Nonproliferative Diabetic Retinopathy (NPDR)**

Nonproliferative diabetic retinopathy is characterized by retinal microaneurysms (Ma), intraretinal hemorrhages (blot, dot, or flame), hard exudates, soft exudates (cotton wool spots), IRMA, venous looping, and/or venous beading. VB, IRMA, and moderate to severe hemorrhage or microaneurysms (H/Ma) are significant risk factors for progression to PDR.<sup>34</sup>

By definition, in mild NPDR there is at least one retinal H/Ma; however, the severity of H/Ma in mild NPDR is less than that depicted in standard photograph 2A of the modified Airlie House classification of DR.<sup>15,32,34</sup> No other diabetic retinal changes are present. In the absence of ME and H/Ma in the macular area, mild NPDR poses no threat to vision. Mild NPDR has a 5 percent risk of progressing to PDR in 1 year and a 15 percent risk of progressing to high-risk PDR within 5 years.

Moderate NPDR differs from mild NPDR in that, in one to three retinal photographic fields, the severity of H/Ma exceeds the severity of H/Ma in standard photograph 2A, or cotton wool spots, VB, or IRMA of mild degree are present. Moderate NPDR has a 12–27 percent risk of progressing to PDR in 1 year and a 33 percent risk of progressing to high-risk PDR within 5 years.<sup>32,34</sup> Careful examination with an indirect ophthalmoscope, fundus contact lens, or fundus lens with the biomicroscope is needed to establish the diagnosis.

Severe NPDR is defined as having, in four retinal quadrants or photographic fields, H/Ma more severe than the H/Ma shown in standard photograph 2A, or as VB (exemplified by that in standard photograph 6B) in two quadrants, or as the presence of moderate IRMA (greater than or equal to those in standard photograph 8A) in at least one retinal quadrant, in the absence of frank neovascularization.<sup>32,34</sup> This "4-2-1" rule is an important clinical tool for determining when DR is at risk of progressing to proliferative disease. Severe NPDR has a 52 percent risk of progressing to PDR in 1 year and a 60 percent risk of progressing to high-risk PDR within 5 years.

In very severe NPDR, two or more criteria for severe NPDR are met. Very severe NPDR carries a substantial risk for progression to PDR in 1 year and to high-risk PDR within 5 years.

**b. Proliferative Diabetic Retinopathy (PDR)**

The most severe form of DR is PDR. Most patients with PDR are at significant risk for vision loss. Characteristics of the disease include new vessels on or within one disc diameter (1 DD) of the optic disc (NVD) or new vessels elsewhere in the retina outside the disc and 1 DD from disc

margin (NVE), fibrous proliferation on or within 1 DD of the optic disc (FPD) or elsewhere on the retina (FPE), PRH, and/or vitreous hemorrhage (VH). PDR that has not reached the high-risk level has a 75 percent likelihood of becoming high risk within a 5-year period.<sup>32,34</sup>

**c. Macular Edema**

Defined as the collection of intraretinal fluid in the macular area of the retina, with or without lipid exudates or cystoid changes, ME can occur at any stage of retinopathy. When macular edema involves or threatens the center of the macula, it is considered "clinically significant." Whether present in NPDR or PDR, this edema results from Ma or other focal or diffuse vascular leakage within or near the macula. Visual acuity is generally compromised when the ME affects the fovea.

**3. International Classification of DR**

In 2001, to simplify classification of DR and standardize communication between retinal health care providers worldwide, a consensus panel, relying on evidence-based studies including the Early Treatment Diabetic Retinopathy Study (ETDRS) and the Wisconsin Epidemiologic Study of Diabetic Retinopathy, prepared an International Classification of Diabetic Retinopathy and Diabetic Macular Edema.<sup>94,95</sup> The proposed classification describes five clinical levels of diabetic retinopathy:

- (1) No apparent retinopathy (no abnormalities)
- (2) Mild NPDR (microaneurysms only)
- (3) Moderate NPDR (more than microaneurysms only but less than severe NPDR)
- (4) Severe NPDR (any of the following: >20 intraretinal hemorrhages in each of four quadrants, definite VB in two or more quadrants, prominent IRMA in at least one quadrant and no PDR)
- (5) PDR (one or more: retinal neovascularization, vitreous hemorrhage, or preretinal hemorrhage).



The panel also defined two broad levels of diabetic macular edema:

- (1) Macular edema apparently absent (no apparent retinal thickening or HE in posterior pole)
- (2) Macular edema apparently present (some apparent retinal thickening or HE in posterior pole). If present, macular edema is subclassified as mild diabetic ME (some retinal thickening or HE in posterior pole but distant from center of the macula), moderate diabetic ME (retinal thickening or HE approaching the center of the macula but not involving the center), or severe diabetic ME (retinal thickening or HE involving the center of the macula).

This classification system reduces the number of levels of DR, simplifies descriptions of the categories, and describes the levels without reference to the standard photographs of the Airlie House Classification of DR.

#### **4. Early Detection and Prevention**

Because the duration of DM is a risk factor for its onset and progression, early diagnosis of DM and DR is essential. Early treatment of DR with photocoagulation surgery reduces the risk of severe vision loss by at least 50–60 percent.<sup>22,31,45,47,48,96,97</sup>



## **II. CARE PROCESS**

This Guideline describes the optometric care provided a patient diagnosed with or suspected of having DM. The components of patient care described are not all-inclusive; professional judgment and individual patient symptoms and findings may have a significant impact on the nature, extent, and course of the services provided. The optometrist may delegate some components of care.

### **A. Diagnosis of Ocular Manifestations of Diabetes Mellitus**

Eye examination may be the basis for the first diagnosis of the patient who is unaware of having a diabetic condition. Ocular examination of a patient suspected of having undiagnosed DM should include all aspects of a comprehensive eye examination.\* The examiner should pay particular attention to the ocular and systemic signs and symptoms of DM, as discussed in this section.

Patients diagnosed with DM need regular eye examinations. Examination of the patient with DM should include all aspects of a comprehensive eye examination, with supplementary testing as indicated to detect and thoroughly evaluate ocular complications. The frequency of examination is determined on the basis of several factors, including the type of DM, duration of the disease, age of the patient, level of patient compliance, concurrent medical status, and both nonretinal and retinal ocular findings. Due to the risk for progression of DR during pregnancy, a diabetic woman should have a baseline examination prior to a planned pregnancy or early in the first trimester of pregnancy.<sup>98,99</sup>

#### **1. Patient History**

##### ***a. Patients with Undiagnosed Diabetes Mellitus***

The history of a person suspected of having DM should include investigation of ocular and systemic complaints and symptoms related to

---

\*Refer to the Optometric Clinical Practice Guideline for Comprehensive Adult Eye and Vision Examination.

DM. Common ocular symptoms of undiagnosed DM include recent onset of blurred or fluctuating vision, or new-onset diplopia. Systemic symptoms may include polyuria, polydipsia, polyphagia, unexplained weight changes, dry mouth, pruritus, leg cramps or pains, impotence, delayed healing of bruises or wounds, and recurrent infections of the skin, genitalia, or urinary tract. Systemic complaints are more common in patients with type 1 diabetes. Patients with type 2 diabetes are frequently asymptomatic.

##### ***b. Patients with Diagnosed Diabetes Mellitus***

For patients diagnosed with DM, the history should encompass both ocular and systemic status, emphasizing in particular any new complaints or symptoms. The clinician should investigate the quality of the patient's vision, to elicit symptoms such as blurred, distorted, or fluctuating vision; diplopia; night vision problems; and flashes or floaters. The history should include questions about previous ocular disease or surgery that might exacerbate the ocular complications of DM.

The clinician should carefully explore the patient's medical history to determine the type and duration of the DM. Studies<sup>82,83,101-104</sup> confirm that the risks for ocular complications are closely related to the duration of the disease (Table 4). Age at the time of onset of DM is not as significant as the duration of the disease in the prediction of complications.<sup>98,101</sup> The optometrist should note the name, address, and telephone number of the patient's primary care physician in the record, to facilitate communication and coordination of the patient's care.

A review of the patient's medical management should encompass diet, oral medications, insulin type and dosage, recent laboratory values for HbA1C, the presence of microalbuminuria or overt proteinuria, lipid values, and method, frequency, and results of self-monitoring of blood glucose. This information provides insight into patient compliance with therapeutic regimens and control of the DM, which may affect the development of ocular complications.<sup>64,65,103,105</sup>



**Table 4**

**Incidence of Diabetic Retinopathy by Type and Duration of Diabetes**

<b>Diabetes</b>	<b>Duration of disease</b>	<b>Incidence of diabetic retinopathy</b>
Type 1	0-4 years	27%
	5-9 years	71%
	10-14 years	54%
	15+ years	38%
Type 2	0-4 years	31%
	5-9 years	32%
	10-14 years	38%
	15+ years	51%

Glycosylated hemoglobin values provide an indication of average blood glucose levels and control of the DM over the prior 6–8 weeks. The level of HbA1C at baseline examination is a strong and independent predictor of incidence and progression of any retinopathy or progression to proliferative retinopathy.<sup>64,65,106</sup> While laboratory values may vary, HbA1C values of 5.0–7.0 percent (normal, 4.0–6.0 percent) usually indicate adequate blood glucose control. The goal is to keep the HbA1C under 7 percent or as close to normal levels as is practicable.

Additional information useful for patient assessment includes a review of other medical problems, medications, and allergy history. Patients diagnosed with DM may have their blood pressure measured at the time of the eye examination, because hypertension is a known risk factor for the development and progression of diabetic retinopathy and nephropathy.<sup>107,108</sup>

**2. Ocular Examination**

The ocular examination should include, but not be limited to, the following evaluations:

- Best corrected visual acuity
- Pupillary reflexes
- Ocular motility
- Visual field screening
- Refraction
- Biomicroscopy
- Tonometry
- Stereoscopic fundus examination with pupillary dilation.

Pupillary dilation with 0.5% or 1.0% tropicamide and 2.5% phenylephrine hydrochloride\* is recommended, unless contraindicated, to achieve maximum visualization of the retina.<sup>101</sup>



**3. Examination Technique**

The optometrist should use binocular indirect ophthalmoscopy with an appropriate condensing lens to examine the retina thoroughly for the presence of DR. Diabetic maculopathy and optic disc changes are best evaluated with stereopsis by fundus biomicroscopy with an appropriate condensing lens, a Hruby lens, or a fundus contact lens, or by stereographic fundus photographs or validated retinal imaging. For maximum visualization of the retina, all examinations should be performed through a dilated pupil, unless contraindicated.

Stereoscopic color fundus photography through a dilated pupil is helpful in detecting and classifying DR.<sup>32-35</sup> Photographic grading of DR compares favorably to clinical examination by ophthalmoscopy in this process. Stereoscopic photography is particularly useful for identifying

---

\*Every effort has been made to ensure that the drug dosage recommendations are accurate at the time of publication of the Guideline. However, as recommendations change due to continuing research and clinical experience, clinicians should verify drug dosage schedules on product information sheets.



clinically significant macular edema (CSME) and for documenting retinal status. Other imaging modalities, such as optical coherence tomography (OCT), play an increasingly important role in diabetes eye care, particularly to demonstrate abnormalities at the vitreo-retinal interface and evaluation for diabetic ME.<sup>109, 110</sup> Proper documentation of retinal status, including the use of drawings or color photographs in the patient's record, is valuable for determining any progression or stability of the DR at future examinations. Use of the standard protocol for color-coding retinal drawings is recommended. It is advisable to note the presence (and the severity) or the absence of neovascularization on the iris (rubeosis iridis or NVI), retinal H/Ma, VB, IRMA, retinal neovascularization, and hard exudates or thickening in the macula. The presence of these lesions helps the examiner determine the level of retinopathy and diagnose ME.

When VH prevents adequate visualization of the retina or when scatter (panretinal) photocoagulation is ineffective, early vitrectomy may be indicated. In such cases, patients need to be referred promptly for evaluation, which may include ultrasound examination, and treatment. The Diabetic Retinopathy Vitrectomy Study showed that early vitrectomy is of benefit in preserving vision in some patients.<sup>45-49</sup>

#### 4. Supplemental Testing

The use of additional procedures may be helpful in diagnosing and evaluating DR. Such procedures include, but are not limited to:

- Color vision assessment
- Contrast sensitivity testing
- Fundus photography or validated retinal imaging
- Gonioscopy
- Macular function assessment
- Optical coherence tomography (OCT)
- Ocular ultrasound (US).

Because hypertension is more prevalent in persons with DM and is a known risk factor for the development and progression of DR,<sup>12,70,108</sup> the

clinician also may measure the blood pressure of the patient suspected of having DM at the time of the eye examination.

### B. Management of Ocular Manifestations of Diabetes Mellitus

#### 1. Basis for Treatment

Treatment decisions depend upon the extent and severity of the patient's ocular condition. Appendix Figure 1 presents a flowchart for the management of the patient with undiagnosed DM. Appendix Figure 2 presents a flowchart outlining the optometric management of the patient diagnosed as having DM. Novel treatment modalities including intravitreal injection of steroids and anti-Vascular Endothelial Growth Factor (VEGF) compounds are commonly used but are still under investigation by the DRCR.net and other clinical trials.<sup>111-114</sup>

##### a. Patients with Undiagnosed Diabetes Mellitus

The patient suspected of having DM should be screened for high blood glucose. The optometrist should refer the patient to a physician for evaluation or request a fasting blood glucose analysis. The patients with fasting blood glucose values greater than or equal to 100 mg/dl but less than 126 mg/dl has IFG and needs to be retested. Optometrists should refer all patients with fasting blood glucose values of 126 mg/dl or greater to physicians for further evaluation or treatment. Most pregnant women should be screened for glucose intolerance. Because a pregnant patient is usually under medical care, her obstetrician should coordinate this examination.

Optometrists must refer patients with undiagnosed DM who present with DR during the initial examination for treatment of their DM. The DR should be managed in accordance with accepted protocols, as outlined in section II.B.1.c of this Guideline, which focuses on retinal complications.

##### b. Patients with Nonretinal Ocular Complications

Management of nonretinal ocular complications of DM should be consistent with current recommendations of care for each condition.

Although a comprehensive discussion of these therapy regimens is beyond the scope of this Guideline, Table 5 briefly outlines the management of nonretinal ocular complications.<sup>115</sup> Treatment protocols should always include patient education and recommendations for followup visits. As part of the proper management of DM, the optometrist should make referrals to other appropriately licensed practitioners for concurrent care when indicated.

**c. Patients with Retinal Complications**

Five major clinical trials provide the scientific basis for standards for clinical management of DR:

- Diabetic Retinopathy Study (DRS, 1971–1975)<sup>9-21</sup>
- Early Treatment Diabetic Retinopathy Study (ETDRS, 1979–1990)<sup>22-44</sup>
- Diabetic Retinopathy Vitrectomy Study (DRVS, 1977–1987)<sup>45-49</sup>
- Diabetes Control and Complications Trial (DCCT, 1983–1993)<sup>6,63-67</sup>
- United Kingdom Prospective Diabetes Study (UKPDS, 1977–1999).<sup>71, 108</sup>

The DRS, ETDRS, and DRVS definitively established the efficacy of laser surgery for PDR and diabetic ME and have provided guidelines concerning the most opportune time for intervention with laser surgery and vitrectomy. The DCCT and UKPDS established the benefits of intensive control of blood glucose levels to reduce the risks of onset and

**Table 5**  
**Management of Nonretinal Ocular Complications of DM**

Category	Ocular Complications	Management*
Functional	Tritan color vision loss	Dilated fundus examination to rule out diabetic maculopathy; counseling; low vision evaluation; review of independent living aids as necessary
	Refractive error changes	Consultation with patient's physician regarding degree of blood glucose control; modification of spectacle prescription as necessary
	Accommodative dysfunction	Consultation with patient's physician regarding degree of blood glucose control; modification of spectacle prescription as necessary
	Visual field defects	Low vision evaluation; orientation and mobility training as necessary
Extraocular muscle anomalies	Mononeuropathies	Neuro-ophthalmology or neurology consultation; temporary prism spectacle prescription as needed; eye patching as indicated
Pupils	Sluggish pupillary reflexes	Workup to rule out optic neuropathy
	Afferent pupillary defects	Workup to rule out optic neuropathy
Conjunctiva	Bulbar microaneurysms	Monitoring
Tear film	Dry eye syndrome	Prescription of artificial tears, ocular lubricants, and other dry eye management techniques; monitoring for corneal complications

**Table 5 (continued)**

Cornea	Reduced corneal sensitivity	Monitoring for abrasions, keratitis, or other ulcerations
	Basement membrane anomalies, recurrent corneal erosions	Prescription of NaCl solution/ointment; artificial tears; patching as necessary
	Descemet's membrane wrinkling	Monitoring
	Endothelial cell changes	Monitoring  NOTE: All corneal injuries should be monitored carefully for secondary infection or evidence of delayed wound healing. This is particularly important in patients who wear contact lenses.
Iris	Depigmentation	Monitoring; routine gonioscopy and tonometry
	Rubeosis iridis (neovascularization on the iris)	Gonioscopy to rule out anterior chamber angle involvement and neovascular glaucoma; dilated fundus examination to search for proliferative retinopathy; referral to retina specialist for possible laser surgery
Lens	Cataracts	Monitoring of both degree of lens opacification and status of any retinopathy; cataract extraction after careful preoperative retinal evaluation; surgery indicated if adequate visualization of the retina is no longer possible
Vitreous	Hemorrhage	Dilated fundus examination; consultation with retina specialist

\* Patient education is an integral part of management for all conditions.

progression of DR and other complications of diabetes for type 1 and type 2 DR, respectively.

The ETDRS modified and extended the Airlie House classification of DR<sup>32,34</sup> to assess the severity and extent of the various lesions of DR. This modification forms the basis of an overall DR severity scale<sup>32</sup> that ranges from the absence of DR to severe VH. Clinical approximations of these levels provide practical guidelines for the clinical diagnosis and management of DR (Table 6).

**Table 6  
Levels of Diabetic Retinopathy**

- I. Nonproliferative Diabetic Retinopathy (NPDR)**
  - A. Mild NPDR
    - At least one Ma
    - One or more of the following:
      - Retinal hemorrhages
      - Hard exudates
      - Soft exudates
    - Definition not met for B, C and D (below) and PDR
  - B. Moderate NPDR
    - H/Ma > standard photo 2A, or
    - Soft exudates, VB, and IRMA definitely present
    - Definition not met for C and D (below) and PDR
  - C. Severe NPDR
    - One of the following:
      - H/Ma ≥ standard photo 2A in all four quadrants
      - VB definitely present in at least two quadrants (see standard photo 6B)
      - IRMA ≥ standard photo 8A in at least one quadrant
    - Definition not met for D (below) and PDR
  - D. Very Severe NPDR
    - Two or more lesions of severe NPDR (C above)

Table 6 (continued)

**II. Proliferative Diabetic Retinopathy (PDR)**

- A. Mild PDR
  - One or more of the following:
    - NVE
    - FPD or FPE present; NVD and NVE absent
  - Definition not met for B and C (below)
- B. Moderate PDR
  - One or more of the following:
    - NVE elevated
    - NVD < standard photo 10A
    - VH/PRH and NVE <1/2 DA; NVD absent
  - Definition not met for C (below)
- C. High-Risk PDR
  - One or more of the following:
    - NVD ≥ 1/4 to 1/3 DA (standard photo 10A)
    - NVD and VH/PRH
    - NVE ≥ 1/2 DA and VH/PRH

**III. Clinically Significant Macular Edema (CSME)**

- One or more of the following:
  - Thickening of the retina ≤500 microns (1/3 DD) from the center of the macula
  - Hard exudates ≤500 microns (1/3 DD) from the center of the macula with thickening of the adjacent retina
  - A zone or zones of retinal thickening ≥1 DA in size, any portion of which is ≤1 DD from the center of the macula

The retinopathy severity scale is valuable as a description of baseline retinopathy levels and identifies the risk for progression of DR. The International Classification of Diabetic Retinopathy and Diabetic Macular Edema, is a simplified severity classification scale that is useful in assessing risk for vision loss (Table 7).

Table 7

**International Clinical Diabetic Retinopathy and Macular Edema Severity Scales**

Diabetic retinopathy	No apparent DR	No abnormalities
	Mild NPDR	Microaneurysms only
	Moderate NPDR	More than Ma only but less than severe NPDR
	Severe NPDR	Any of the following: <ul style="list-style-type: none"> <li>• &gt;20 intraretinal hemorrhages in each of 4 quadrants</li> <li>• Definite VB in ≥2 quadrants</li> <li>• Prominent IRMA in ≥1 quadrant</li> </ul>
Diabetic macular edema	Diabetic ME apparently absent	No apparent retinal thickening or HE in posterior pole
	Diabetic ME apparently present	Some apparent retinal thickening or HE in posterior pole
	• Mild diabetic ME	Some retinal thickening or HE in posterior pole but distant from the center of the macula
	• Moderate diabetic ME	Retinal thickening or HE approaching the center of the macula but not involving the center

When indicated (generally for levels of moderate NPDR or worse, any PDR, any macular edema, neovascularization of the iris, or unexplained vision loss), the optometrist should refer the person with DM to an ophthalmologist skilled in treating diseases of the retina, or to a retina specialist.

## **2. Available Treatment Options**

### **a. Nonproliferative Diabetic Retinopathy**

An annual dilated eye examination and fundus photographs, if indicated, are generally sufficient for the patient with mild NPDR, as long as there is neither ME nor a coincident medical condition, such as hypertension, renal disease, or pregnancy. The patient's primary care physician should be informed of eye examination results, even when retinopathy is minimal or not present.

For patients with moderate NPDR, fundus photography is strongly suggested, and repeat evaluation in 6–12 months is appropriate in the absence of ME or complicating medical or risk factors. Although the patient with mild or moderate NPDR generally is not a candidate for scatter (panretinal) laser treatment, the presence of ME requires more frequent evaluation, consultation with a retina specialist, and, in the presence of CSME, probably focal laser photocoagulation. Misdiagnosis of moderate NPDR is hazardous because of significant underestimation of a patient's risk for progression to proliferative retinopathy.

Followup every 2–3 months in consultation with a retina specialist is advisable for patients with severe or very severe NPDR. Scatter laser photocoagulation may be indicated, depending on the clinical judgment of the retina specialist. Studies also suggest that type 2 diabetic patients are more likely to benefit from scatter photocoagulation prior to the development of high-risk PDR.<sup>39,116</sup> Severe and very severe NPDR (as well as PDR that is not high risk) may require early scatter laser surgery, particularly when neovascularization of the disc has occurred or elevated numbers of new vessels are present.

Patients with moderate NPDR or worse should be considered for focal laser treatment of ME, regardless of whether the ME is clinically significant, in preparation for the possible future need for scatter photocoagulation. Focal laser surgery for CSME is strongly indicated for patients with severe NPDR because of the risk for the development of PDR and high-risk PDR.<sup>107</sup> Consultation with a retina specialist is indicated.<sup>116</sup>

### **b. Proliferative Diabetic Retinopathy**

Proliferative diabetic retinopathy is marked by new vessel growth on the optic disc or elsewhere on the retina, or by the proliferation of fibrous tissue. Proliferative retinopathy that has not reached the high-risk level has a 75 percent likelihood of becoming high-risk PDR within a 5-year period. Scatter laser photocoagulation may be indicated, and even when ME is not clinically significant, the patient with PDR may benefit from treatment. Prompt referral to a retina specialist is indicated.

The DRS and ETDRS conclusively demonstrated that scatter (panretinal) laser photocoagulation surgery significantly reduces the risk for severe vision loss from PDR. Furthermore, these studies identified specific retinal lesions that pose a significant threat of vision loss.<sup>32,34</sup>

Patients with high-risk PDR require immediate referral to a retina specialist for scatter laser photocoagulation. High-risk PDR is characterized by any one or more of the following lesions:<sup>11</sup>

- NVD approximately one-fourth to one-third of the disc area (DA) or more in size (i.e.,  $\geq$ NVD in standard photo 10A)
- NVD less than one-fourth DA in size when fresh VH or PRH is present
- NVE greater than or equal to one-half DA in size when fresh VH or PRH is present.

To identify high-risk PDR, the examiner must pay attention to the presence or absence of retinal neovascularization, the location and

severity of any neovascularization, and the presence or absence of preretinal or vitreous hemorrhages. The risk for severe vision loss can be reduced by at least 50 percent by initiating scatter laser surgery for eyes with high-risk PDR; consequently, any patient who demonstrates high-risk PDR should be referred immediately (within 24–48 hours) to a retina specialist.

Eyes in which PDR has not advanced to the high-risk stage should be considered analogous to eyes with high-risk PDR. Many retina specialists perform scatter laser photocoagulation in eyes with less than high-risk PDR, particularly when there are extenuating circumstances, such as patient noncompliance, the development of cataracts, difficulty in managing DM or associated medical conditions (e.g., hypertension, nephropathy), or pregnancy. These same considerations pertain to patients with severe or very severe NPDR.<sup>39,116</sup> Patients with type 2 diabetes or type 1 diabetes of long duration may benefit from earlier laser treatment, prior to the development of high-risk PDR.<sup>116</sup>

The goal of laser surgery is to induce regression of neovascularization without VH or fibrovascular proliferation that results in traction retinal detachment or macular dragging. Any patient with PDR should be referred to a retina specialist promptly for further evaluation and photocoagulation treatment, as clearly supported by the DRS and ETDRS. Timely and appropriate laser and vitrectomy surgery can significantly reduce the 5-year risk for severe vision loss from PDR. In the ETDRS, 4 percent of eyes with PDR that were treated had severe vision loss within 5 years, and 1 percent of patients had such loss. Only 5 percent of ETDRS patients with PDR became legally blind.

### **c. Macular Edema**

Management of patients with ME involves consideration of both the significance of the edema and the nature of any other retinopathy present. ME is divided into two categories; the less severe, non-clinically significant ME, usually does not require laser surgery. Such patients should be re-examined within 3–4 months in consultation with a retina specialist. Followup can be more frequent if required for proper management of the retinopathy. Referral for fluorescein angiography

(FA) may be indicated to identify treatable lesions, although FA generally is not needed for diagnosis.<sup>22,23,25,27</sup>

As defined by the ETDRS, clinically significant macular edema includes any one of the following lesions:<sup>22,24</sup>

- Retinal thickening at or within 500 microns (one-third DD) from the center of the macula, or
- Hard exudates at or within 500 microns (one-third DD) from the center of the macula, if there is thickening of the adjacent retina, or
- An area or areas of retinal thickening at least 1 DA in size, at least part of which is within 1 DD of the center of the macula.

Patients with CSME should be referred promptly for FA and focal laser photocoagulation treatment.<sup>22</sup> Follow-up examination should be scheduled 3–4 months after treatment. When the retina consultant defers treatment, the retina consultant's follow-up examination generally occurs within 3 months.

The management of diabetic papillopathy and ischemic optic neuropathy may require consultation with a neuro-ophthalmologist or neurologist to rule out all other potential etiologies, such as space-occupying lesions.

The clinical appearance of the nerve fiber layer may be affected by scatter (panretinal) photocoagulation to treat the microvascular complications of DR; however, no significant change in the optic disc contour or cup-to-disc ratio has been documented.<sup>106</sup> Optic disc pallor without increased cup-to-disc ratio may result from quiescent PDR, whether occurring spontaneously or following scatter (panretinal) laser photocoagulation.<sup>100</sup>

### **3. Patient Education**

Virtually all patients with DM will develop some form of DR at some point during the course of the disease. Therefore, it is important for them to learn about the disease process and the risks for developing ocular

signs and symptoms that may result in vision loss. Optometrists should inform patients that retinopathy may exist even when vision is good. Patients should be encouraged to report all ocular symptoms (e.g., blurred vision, flashes, and floaters), inasmuch as DM may be the underlying etiology. Optometrists should help patients understand that timely followup examinations and management are critical for early diagnosis and intervention, when indicated, to reduce the risk of vision loss from DR. Patients also should be informed about their higher risk for other nonretinal ocular complications, such as cataracts, neovascular glaucoma, and open angle glaucoma.<sup>118</sup>

Optometrists should inform their patients about the relationship between the level of control of diabetes and the subsequent development of ocular and other medical complications. Specific emphasis should be placed on the benefit of any reduction in elevated HbA1C in lowering the risk of damage. A 1 percent rise in HbA1C (from 7 to 8 percent) increases the progression of nonproliferative retinopathy by 44 percent over a 10-year period. For the patient with proliferative retinopathy, the same 1 percent increase in HbA1C results in 145 percent progression over 10 years.<sup>119</sup> Special care is needed in the approach to elderly patients; because their risks and benefits may be different, the discussion and instruction will have to be individualized.<sup>120</sup>

Optometrists should inform patients that diabetic nephropathy, as manifested by microalbuminuria, requires aggressive early treatment. Treatment modalities include improved glycemic control and the timely use of the angiotensin-converting enzyme (ACE) inhibitors. The captopril type 1 diabetes study showed that ACE inhibitors reduce by 50 percent the progression to end-stage renal disease, which necessitates dialysis or kidney transplantation, and can result in death.<sup>121,122</sup> Proper monitoring and timely treatment can result in subsequent saving of sight for persons with diabetes mellitus.

Finally, optometrists should advise all patients about organizations that provide resources and support for patients with DM. (A list of organizations is available from the AOA Clinical Care Group.)

#### **4. Prognosis and Followup**

All patients with DM are at risk for the development of ocular-related complications. Compliance with treatment recommendations to maintain close control of their blood glucose levels is a significant factor in slowing the development and progression of ocular complications of DM.

Diabetic patients who do not have DR should be re-examined annually. The followup examination of patients with DR should be scheduled in accordance with the clinical trials protocols. Proper diagnosis is crucial because misdiagnosis by just one level underestimates a patient's risk of developing PDR in 1 year by 50 percent or more (Appendix Figure 3).

Focal laser photocoagulation for CSME reduces the risk of moderate vision loss (i.e., a doubling of the visual angle) from nearly 30 percent to approximately 12 percent. Scatter (panretinal) laser photocoagulation reduces the risk of severe vision loss (best visual acuity  $\leq 5/200$ ) to less than 2 percent. Laser surgery, therefore, greatly improves the prognosis for maintaining useful vision.

Following successful treatment, patients with PDR should be re-examined every 2–4 months. The optometrist may perform a peripheral visual field examination approximately 6 months after treatment. Color photography also may be useful in monitoring post-treatment status. The management of patients with PDR needs to be coordinated with the recommendations of the retina specialist.

Appropriate communication with the patient's primary care physician (as with any referral consultant) is critical for proper coordination of the patient's care. Due to the nature of DM, a multidisciplinary approach to patient management is essential. All health care personnel involved with the patient's care should be aware of the patient's overall medical status. Written letters or reports are useful in accomplishing this task. These letters also provide permanent documentation for the patient's record. The patient's primary care physician must be involved in all aspects of the health care.

The patient with diabetic ME, or with suspected diabetic ME, should be referred promptly, usually within 2–4 weeks, to a retina specialist for evaluation. The patient with high-risk PDR should be referred to a retina specialist immediately, usually within 24–48 hours, for consideration of scatter (panretinal) laser surgery. Patients whose PDR is less than high risk or who have signs of severe or very severe NPDR should be referred for consultation with retina specialists because they may require laser surgery. The optometrist should communicate with the diabetic patient's primary care physician following each eye examination.

Intravitreal steroid injections, such as triamcinolone, and intravitreal anti-VEGF injections, such as avastin or lucentis, are sometimes used in clinical practice to treat macular edema, despite the lack of definitive studies on their effectiveness or safety. These modalities are currently under rigorous investigation to further define their role.

#### **5. Management of Patients with Severe, Irreversible Vision Loss**

Patients with DR are at risk for both permanent loss of visual acuity and loss of functional vision, including:

- Reduced central visual acuity and central scotoma from diabetic maculopathy
- Loss of peripheral visual field
- Difficulty with vision in dim light, secondary to retinal ischemia or panretinal laser photocoagulation
- Vision loss secondary to residual effects from vitreous hemorrhage, preretinal hemorrhage, or traction retinal detachment.

Because standard corrective eyeglasses and contact lenses may not alleviate the functional vision problems associated with DR, patients with DR may need low vision rehabilitation entailing orientation and mobility training, nonoptical aids, and other independent living aids or devices. For example, optical aids alone may be inadequate for patients who need to manage their medication regimens or to self-monitor blood

glucose. Due to acquired color vision defects, the diabetic patient has particular difficulty using color-comparison systems for self-monitoring blood glucose levels<sup>123</sup> and may require a self-monitoring system with a digital display meter or voice response. Another problem for the DM patient is loss of tactile sensation related to peripheral neuropathy. This loss may affect the patient's ability to perform routine tasks safely, such as meal preparation, dialing the telephone, and writing.

When a standard corrective prescription or a less complex low vision device cannot satisfy the visual requirement, the patient's rehabilitation may necessitate a specialized low vision consultation or appropriate patient counseling. The patient should be evaluated to determine his/her potential to benefit from comprehensive low vision rehabilitation that would reduce the debilitating effects of vision loss.\*

Patients with significant reduction of visual acuity or functional vision loss may be unable to continue their usual employment. Occupational or vocational rehabilitation may help patients achieve more fulfilling, self-sustaining lifestyles.<sup>124</sup> Optometrists should make referrals only after discussing with their patients their willingness to participate in such consultations.

The fear of vision loss associated with DR can result in a high level of anxiety for any patient with retinopathy, including the patient with good functional vision.<sup>125,126</sup> Even patients without retinopathy or other ocular complications may have personal concerns about DM (e.g., problems accepting the disease, adapting to it, and adjusting to emotional and social changes). Referral for psychosocial counseling is indicated for any patient who may have difficulty dealing with the issues associated with DM or DR. An early counseling visit may be beneficial for a family with a child who has DM. The optometrist should make educational literature and a list of support agencies and other resources available to the patient.

---

\*Refer to the Optometric Clinical Practice Guideline on Care of the Patient with Low Vision.

## CONCLUSION

Until modalities are in place to prevent or cure diabetic retinopathy and other complications of diabetes mellitus, emphasis must be placed on identification, careful followup, and timely treatment, including laser photocoagulation, for patients with DR and diabetic eye disease. Proper care will result in reduction of personal suffering for those involved, and a substantial cost savings for the involved individuals, their families, and the country as a whole. Therefore, strict guidelines have been established for the ocular care of people with diabetes.<sup>87,127</sup>

Optometrists should inform all diabetic patients of the possibility of developing retinopathy, with or without symptoms, and of the associated threat of vision loss. They should discuss the results of the DCCT and UKPDS and encourage patients to see their diabetes care providers to work toward achieving the goals for diabetes control published by the American Diabetes Association. Optometrists should discuss with patients the natural course and treatment of DR and stress the importance of routine eye examinations.

## III. REFERENCES

1. Harris MI, Hadden WC, Knowler WC, Bennett PH. Prevalence of diabetes and impaired glucose tolerance and plasma glucose levels in U.S. population aged 20-74 yr. *Diabetes* 1987; 36:523-34.
2. The Eye Disease Prevalence Research Group. The Prevalence of Diabetic retinopathy among Adults in the United States. *Arch Ophthalmol* 2004;122:552-563.
3. Zhang X, Gregg EW, Cheng YJ, et al. Diabetes mellitus and visual impairment. National Health and Nutrition Examination Survey, 1999-2004. *Arch Ophthalmol* 2008;126:1421-1427.
4. Aiello LM, Rand LI, Briones JC, et al. Diabetic retinopathy in Joslin Clinic patients with adult-onset diabetes. *Ophthalmology* 1981; 88:619-23.
5. Sloan FA, Belsky D, Ruiz D, Lee P. Changes in incidence of diabetes mellitus-related eye disease among US elderly persons, 1994-2005. *Arch Ophthalmol* 2008;126:1548-1553
6. Diabetes Control and Complications Trial Research Group. The effect of intensive treatment of diabetes on the development and progression of long-term complications in insulin dependent diabetes mellitus. *N Engl J Med* 1993; 329:977-86.
7. Witkin SR, Klein R. Ophthalmologic care for persons with diabetes. *JAMA* 1984; 251:2534-7.
8. Sprafka JM, Fritsche TL, Baker R, et al. Prevalence of undiagnosed eye disease in high-risk diabetic individuals. *Arch Intern Med* 1990; 150:857-61.
9. Diabetic Retinopathy Study Research Group. Preliminary report on effects of photocoagulation therapy. DRS Report No. 1. *Am J Ophthalmol* 1976; 81:383-96.

References 47

10. Diabetic Retinopathy Study Research Group. Photocoagulation treatment of proliferative diabetic retinopathy. DRS Report No. 2. *Ophthalmology* 1978; 85:82-106.
11. Diabetic Retinopathy Study Research Group. Four risk factors for severe visual loss in diabetic retinopathy. DRS Report No. 3. *Arch Ophthalmol* 1979; 97:654-5.
12. Diabetic Retinopathy Study Research Group. A short report of long-term results. DRS Report No. 4. Proc 10th Congr Intl Diabetes Fed, Vienna, Sept 9-14, 1979. Amsterdam: Excerpta Medica 1980:789-94 (Intl Congress Series: 500).
13. Diabetic Retinopathy Study Research Group. Photocoagulation treatment of proliferative diabetic retinopathy: relationship of adverse treatment effects to retinopathy severity. DRS Report No. 5. *Dev Ophthalmol* 1981; 2:248-61.
14. Diabetic Retinopathy Study Research Group. Design methods and baseline results. DRS Report No. 6. *Invest Ophthalmol Vis Sci* 1981; 21(1, part 2):1-226.
15. Diabetic Retinopathy Study Research Group. A modification of the Airlie House classification of diabetic retinopathy. DRS Report No. 7. *Invest Ophthalmol Vis Sci* 1981; 21(1, part 2):1-226.
16. Diabetic Retinopathy Study Research Group. Photocoagulation treatment of proliferative diabetic retinopathy. Clinical applications of Diabetic Retinopathy Study (DRS) findings. DRS Report No. 8. *Ophthalmology* 1981; 88:583-600.
17. Ederer F, Podgor MJ, DRS Research Group. Assessing possible late treatment effects in stopping a clinical trial early: a case study. DRS Report No. 9. *Control Clin Trials* 1984; 5:373-81.

48 Diabetes Mellitus

18. Rand LI, Prud'homme GJ, Ederer F, Canner PL, DRS Research Group. Factors influencing the development of visual loss in advanced diabetic retinopathy. DRS Report No. 10. *Invest Ophthalmol Vis Sci* 1985; 26:983-91.
19. Kaufman SC, Ferris FL, Swartz M, DRS Research Group. Intraocular pressure following panretinal photocoagulation for diabetic retinopathy. DRS Report No. 11. *Arch Ophthalmol* 1987; 105:807-9.
20. Ferris FL, Podgor MJ, Davis MD, Diabetic Retinopathy Study Research Group. Macular edema in diabetic retinopathy study patients. DRS Report No. 12. *Ophthalmology* 1987; 94:754-60.
21. Diabetic Retinopathy Study Research Group. Indications for photocoagulation treatment of diabetic retinopathy. DRS Report No. 14. *Int Ophthalmol Clin* 1987; 27:239-53.
22. Early Treatment Diabetic Retinopathy Study Research Group. Photocoagulation for diabetic macular edema. ETDRS Report No. 1. *Arch Ophthalmol* 1985; 103:1796-806.
23. Early Treatment Diabetic Retinopathy Study Research Group. Treatment techniques and clinical guidelines for photocoagulation of diabetic macular edema. ETDRS Report No. 2. *Ophthalmology* 1987; 94:761-74.
24. Early Treatment Diabetic Retinopathy Study Research Group. Techniques for scatter and local photocoagulation treatment of diabetic retinopathy. ETDRS Report No. 3. *Int Ophthalmol Clin* 1987; 27:254-64.
25. Early Treatment Diabetic Retinopathy Study Research Group. Photocoagulation for diabetic macular edema. ETDRS Report No. 4. *Int Ophthalmol Clin* 1987; 27:265-72.
26. Early Treatment Diabetic Retinopathy Study Research Group. Case reports to accompany early treatment diabetic retinopathy

References 49

- study reports No. 3 and 4. *Int Ophthalmol Clin* 1987; 27:273-333.
27. Kinyoun J, Barton F, Fisher M, et al. Early Treatment Diabetic Retinopathy Study Research Group. Detection of diabetic macular edema: ophthalmoscopy versus photography. ETDRS Report No. 5. *Ophthalmology* 1989; 96:746-51.
28. Prior MJ, Prout T, Miller D, et al. Early Treatment Diabetic Retinopathy Study Research Group. C-peptide and the classification of diabetes mellitus patients in the Early Treatment Diabetic Retinopathy Study. ETDRS Report No. 6. *Ann Epidemiol* 1993; 3:9-17.
29. Early Treatment Diabetic Retinopathy Study Research Group. Design and baseline patient characteristics. ETDRS Report No. 7. *Ophthalmology* 1991; 98:741-56.
30. Early Treatment Diabetic Retinopathy Study Research Group. Effects of aspirin treatment on diabetic retinopathy. ETDRS Report No. 8. *Ophthalmology* 1991; 98:757-65.
31. Early Treatment Diabetic Retinopathy Study Research Group. Early photocoagulation for diabetic retinopathy. ETDRS Report No. 9. *Ophthalmology* 1991; 98:766-85.
32. Early Treatment Diabetic Retinopathy Study Research Group. Grading diabetic retinopathy from stereoscopic color fundus photographs: an extension of the modified Airlie House classification. ETDRS Report No. 10. *Ophthalmology* 1991; 98:786-806.
33. Early Treatment Diabetic Retinopathy Study Research Group. Classification of diabetic retinopathy from fluorescein angiograms. ETDRS Report No. 11. *Ophthalmology* 1991; 98:807-22.

50 Diabetes Mellitus

34. Early Treatment Diabetic Retinopathy Study Research Group. Fundus photographic risk factors for progression of diabetic retinopathy. ETDRS Report No. 12. *Ophthalmology* 1991; 98:823-33.
35. Early Treatment Diabetic Retinopathy Study Research Group. Fluorescein angiographic risk factors for progression of diabetic retinopathy. ETDRS Report No. 13. *Ophthalmology* 1991; 98:834-40.
36. Early Treatment Diabetic Retinopathy Study Research Group. Aspirin effects on mortality and morbidity in patients with diabetes mellitus. ETDRS Report No. 14. *JAMA* 1992; 268:1292-300.
37. Chew EY, Williams GA, Burton TC, et al. Early Treatment Diabetic Retinopathy Study Research Group. Aspirin effects on the development of cataracts in patients with diabetes mellitus. ETDRS Report No. 16. *Arch Ophthalmol* 1992; 110:339-42.
38. Flynn HW Jr, Chew EY, Simons BD, et al. Early Treatment Diabetic Retinopathy Study Research Group. Pars plana vitrectomy in the early treatment diabetic retinopathy study. ETDRS Report No. 17. *Ophthalmology* 1992; 99:1351-57.
39. Davis MD, Fisher MR, Gangnon RE, et al. Early Treatment Diabetic Retinopathy Study Research Group. Risk factors for high-risk proliferative diabetic retinopathy and severe visual loss. ETDRS Report No. 18. *Invest Ophthalmol Vis Sci* 1998; 39:233-52.
40. Early Treatment Diabetic Retinopathy Study Research Group. Focal photocoagulation treatment of diabetic macular edema: relationship of treatment effect to fluorescein angiographic and other retinal characteristics at baseline. ETDRS Report No. 19. *Arch Ophthalmol* 1995; 113:1144-55.

41. Chew EY, Klein ML, Murphy RP, et al. Early Treatment Diabetic Retinopathy Study Research Group. Effects of aspirin on vitreous/preretinal hemorrhage in patients with diabetes mellitus. ETDRS Report No. 20. Arch Ophthalmol 1995; 113:52-5.
42. Braun CI, Benson WE, Remaley NA, et al. Early Treatment Diabetic Retinopathy Study Research Group. Accommodative amplitudes in the early treatment diabetic retinopathy study: ETDRS Report No. 21. Retina 1995; 15:275-81.
43. Chew EY, Klein ML, Ferris FL III, et al. Early Treatment Diabetic Retinopathy Study Research Group. Association of elevated serum lipid levels with retinal hard exudate in diabetic retinopathy. ETDRS Report No. 22. Arch Ophthalmol 1996; 114:1079-84.
44. Fong DS, Segal PP, Myers F, et al. Early Treatment Diabetic Retinopathy Study Group. Subretinal fibrosis in diabetic macular edema. Arch Ophthalmol 1997; 115:873-7.
45. Diabetic Retinopathy Vitrectomy Study Research Group. Two-year course of visual acuity in severe proliferative diabetic retinopathy with conventional management. DRVS Report No. 1. Ophthalmology 1985; 92:492-502.
46. Diabetic Retinopathy Vitrectomy Study Research Group. Early vitrectomy for severe vitreous hemorrhage in diabetic retinopathy. Two-year results of a randomized trial. DRVS Report No. 2. Arch Ophthalmol 1985; 103:1644-52.
47. Diabetic Retinopathy Vitrectomy Study Research Group. Early vitrectomy for severe proliferative diabetic retinopathy in eyes with useful vision. Results of a randomized trial. DRVS Report No. 3. Ophthalmology 1988; 95:1307-20.
48. Diabetic Retinopathy Vitrectomy Study Research Group. Early vitrectomy for severe proliferative diabetic retinopathy in eyes

- with useful vision. DRVS Report No. 4. Ophthalmology 1988; 95:1321-34.
49. Diabetic Retinopathy Vitrectomy Study Research Group. Early vitrectomy for severe vitreous hemorrhage in diabetic retinopathy. Four-year results of a randomized trial. DRVS Report No. 5. Arch Ophthalmol 1990; 108:958-64.
50. Appiah AP, Ganthier R, Watkins N. Delayed diagnosis of diabetic retinopathy in black and Hispanic patients with diabetes mellitus. Ann Ophthalmol 1991; 23:156-8.
51. American Diabetes Association. Screening for diabetes. Diabetes Care 1998; 21(suppl 1):s20-s22.
52. Expert Committee on the Diagnosis and Classification of Diabetes Mellitus. Diagnosis and Classification of Diabetes Mellitus. Diabetes Care 2009; 32(suppl 1):s62-s67.
53. American Diabetes Association. All About Diabetes. <http://www.diabetes.org/about-diabetes.jsp> (accessed 10 Feb 2009).
54. American Diabetes Association. Standards of medical care in diabetes—2007. Diabetes Care 2009; 32(suppl 1):s13-61.
55. World Health Organization Study Group. Prevention of diabetes mellitus. Technical Report No. 844, Geneva, 1994.
56. The International Expert Committee. International Expert Committee report on the role of A1C Assay in the diagnosis of diabetes. *Diabetes Care*. 2009 32:1327-1334.
57. Fagot-Campagna A, Pettitt DJ, Engelgau MM, et al. Type 2 diabetes among North American children and adolescents: An epidemiologic review and a public health perspective. J Pediatr 2000; 136:664-72.

58. American Diabetes Association. Standards of medical care in diabetes—2009. *Diabetes Care* 2009; 32(suppl 1):s15.
59. American Diabetes Association. Standards of medical care in diabetes—2009. *Diabetes Care* 2009; 32(suppl 1):s13-14.
60. American Diabetes Association. Nutritional recommendations and principles for individuals with diabetes mellitus. *Diabetes Care* 1998; 21(suppl 1):s32-s35.
61. Bressler R, Johnson DG. Pharmacological regulation of blood glucose levels in non-insulin-dependent diabetes mellitus. *Arch Intern Med* 1997; 157:836-48.
62. Nissen SE, Wolski K. Effect of Rosiglitazone on the risk of myocardial infarction and death from cardiovascular causes. *N Engl J Med* 2007;356:2457-71.
63. Diabetes Control and Complications Trial Research Group. Are continuing studies of metabolic control and microvascular complications in insulin-dependent diabetes mellitus justified? *N Engl J Med* 1988; 318:246-50.
64. Diabetes Control and Complications Trial Research Group. The relationship of glycemic exposure (HbA1C) to the risk of development and progression of retinopathy in the Diabetes Control and Complications Trial. *Diabetes* 1995; 44:968-83.
65. Diabetes Control and Complications Group. Progression of retinopathy with intensive versus conventional treatment in the Diabetes Control and Complications Trial. *Ophthalmology* 1995; 102:647-61.
66. Diabetes Control and Complications Trial Research Group. Hypoglycemia in the Diabetes Control and Complications Trial. *Diabetes* 1997; 46:271-86.

67. Diabetes Control and Complications Trial Research Group. Lifetime benefits and costs of intensive therapy as practiced in the Diabetes Control and Complications Trial. *JAMA* 1996; 276:1409-15.
68. Writing Team for the Diabetes Control and Complications Trial/Epidemiology of Diabetes Interventions and Complications Research Group. Effect of intensive therapy on the microvascular complications of type 1 diabetes mellitus. *JAMA* 2002; 287:2563-9.
69. Ohkubo Y, Kishikawa H, Araki E, et al. Intensive insulin therapy prevents the progression of diabetic microvascular complications in Japanese patients with non-insulin-dependent diabetes mellitus: a randomized prospective 6-year study. *Diabetes Res Clin Pract* 1995; 28:103-17.
70. Reichard P, Nilsson BY, Rosenqvist U. The effect of long-term intensified insulin treatment on the development of microvascular complications of diabetes mellitus. *N Engl J Med* 1993; 329:304-9.
71. Intensive blood glucose control with sulfonylureas or insulin compared with conventional treatment and risk of complications in patients with type 2 diabetes. UKPDS33. UK Prospective Diabetes Study Group. *Lancet* 1998; 352:837-53.
72. Holman RR, Paul SK, Bethel MA, Matthew DR, Neil AW. 10-year follow-up of intensive glucose control in type 2 diabetes. *N Engl J Med* 2008;359:1577-89.
73. Diabetes Control and Complications Trial/Epidemiology of Diabetes Interventions and Complications Research Group. Retinopathy and nephropathy in patients with type 1 diabetes four years after a trial of intensive therapy. *N Engl J Med* 2000; 342:381-9.

74. White NH, Sun W, Cleary PA, et al. Prolonged effect of intensive therapy on the risk of retinopathy complications in patients with type 1 diabetes mellitus: 10 years after the Diabetes Control and Complications Trial. *Arch Ophthalmol* 2008;126:1707-15.
75. American Diabetes Association. Standards of medical care for patients with diabetes mellitus. *Diabetes Care* 1998; 21(suppl 1):s23-31.
76. Kahn CR, Shechter Y. Insulin, oral hypoglycemic agents, and the pharmacology of the endocrine pancreas. In: Rall TW, Nies AS, Taylor P, eds. *Goodman and Gilman's the pharmacological basis of therapeutics*, 8th ed. Elmsford, NY: Pergamon Press; 1990:1463-95.
77. National Diabetes Information Clearinghouse (NDIC). National Diabetes Statistics, 2007. <http://diabetes.niddk.nih.gov/dm/pubs/statistics/index.htm>. (accessed 12 Feb 2009).
78. Cowie CC, Rust KF, Byrd-Holt D, et al. Prevalence of diabetes and impaired fasting glucose in adults—United States, 1999-2000. *MMWR* 2003; 52;833-7.
79. Wilson PW, Anderson KM, Kannel WB. Epidemiology of diabetes mellitus in the elderly. The Framingham Study. *Am J Med* 1986; 80:3-9.
80. LaPorte RE, Matsushima M, Chang YF. Prevalence and incidence of insulin dependent diabetes mellitus. *Diabetes in America*, 2nd ed. NIH publication. Washington, DC: U.S. Government Printing Office, 1995:37.
81. Kenny SJ, Aubert RE, Geiss LS. Prevalence and incidence of non-insulin dependent diabetes mellitus. *Diabetes in America*, 2nd ed. NIH publication. Washington, DC: U.S. Government Printing Office, 1995:47.

82. Klein R, Klein BE, Moss SE, et al. The Wisconsin Epidemiologic Study of Diabetic Retinopathy. IX. Four-year incidence and progression of diabetic retinopathy when age at diagnosis is less than 30 years. *Arch Ophthalmol* 1989; 107:237-43.
83. Klein R, Klein BE, Moss SE, et al. The Wisconsin Epidemiologic Study of Diabetic Retinopathy. X. Four-year incidence and progression of diabetic retinopathy when age at diagnosis is 30 years or more. *Arch Ophthalmol* 1989; 107:244-9.
84. Aiello LM, Aiello LP, Cavallerano JD. Ocular Complications of Diabetes Mellitus. In Kahn CR, Weir GC, King GL, Jacobson AM, Moses AC, Smith RJ (ed.). *Joslin's Diabetes Mellitus*. Lippincott, Williams & Wilkins. Philadelphia, PA. 2005, pp. 901-924.
85. Bernth-Petersen P, Bach E. Epidemiologic aspects of cataract surgery. III. Frequencies of diabetes and glaucoma in a cataract population. *Acta Ophthalmol (Copenh)* 1983; 61:406-16.
86. American Diabetes Association. Executive Summary: Standards of medical care in diabetes—2009. *Diabetes Care* 2009; 32(suppl 1):s9-10.
87. American Diabetes Association. Position statement: diabetic retinopathy. *Diabetes Care* 1998; 21(suppl 1):s47-49.
88. Bursell SE, Clermont AC, Kinsley BT, et al. Retinal blood flow changes in patients with insulin-dependent diabetes mellitus and no diabetic retinopathy. *Invest Ophthalmol Vis Sci* 1996; 37(5):886-97.
89. Fong D, Bursell SE, Clermont AC, et al. Von Willebrand factor and retinal circulation in early-stage retinopathy of type 1 diabetes. *Diabetes Care* 2000;23:1694-8.

90. Appen RE, Chandra SR, Klein R, Myers FL. Diabetic papillopathy. *Am J Ophthalmol* 1980; 90:203-9.
91. Heller SR, Tattersall RB. Optic disc swelling in young diabetic patients: a diagnostic dilemma. *Diabet Med* 1987; 4:260-4.
92. Barr CC, Glaser JS, Blankenship G. Acute disc swelling in juvenile diabetes. Clinical profile and natural history of 12 cases. *Arch Ophthalmol* 1980; 98:2185-92.
93. Yanko L, Goldbourt U, Michaelson IC, et al. Prevalence and 15-year incidence of retinopathy and associated characteristics in middle-aged and elderly diabetic men. *Br J Ophthalmol* 1983; 67:759-65.
94. Wilkinson CP, Ferris FL, Klein RE, et al. Proposed International Clinical Diabetic Retinopathy and Diabetic Macular Edema Disease Severity Scales. *Ophthalmology* 2003; 110:1677-82.
95. Chew EY. A simplified diabetic retinopathy scale. *Ophthalmology* 2003; 110:1675-6.
96. Vander Zwaag R, Connor M, Dickson HD, Runyan JW. Costs of diabetes care. In: Davidson JK, ed. *Clinical diabetes mellitus*, 2nd ed. New York: Thieme Medical Publishers Inc.; 1991:717-22.
97. Javitt JC, Canner JK, Frank RG, et al. Detecting and treating retinopathy in patients with type I diabetes mellitus. A health policy model. *Ophthalmology* 1990; 97:483-94.
98. Sunness JS. The pregnant woman's eye. *Surv Ophthalmol* 1988; 32:219-38.
99. Moloney JB, Drury MI. The effect of pregnancy on the natural course of diabetic retinopathy. *Am J Ophthalmol* 1982; 93:745-56.

100. Johns KJ, Leonard-Martin T, Feman SS. The effect of panretinal photocoagulation on optic nerve cupping. *Ophthalmology* 1989; 96:211-6.
101. Huber MJ, Smith SA, Smith SE. Mydriatic drugs for diabetic patients. *Br J Ophthalmol* 1985; 69:425-7.
102. Klein R, Klein BE, Moss SE, et al. The Wisconsin Epidemiologic Study of Diabetic Retinopathy. III. Prevalence and risk of diabetic retinopathy when age at diagnosis is 30 or more years. *Arch Ophthalmol* 1984; 102:527-32.
103. Kostraba JN, Dorman JS, Orchard TJ, et al. Contribution of diabetes duration before puberty to development of microvascular complications in IDDM subjects. *Diabetes Care* 1989; 12:686-93.
104. Klein R, Klein BE, Moss SE, et al. The Wisconsin epidemiologic study of diabetic retinopathy. II. Prevalence and risk of diabetic retinopathy when age at diagnosis is less than 30 years. *Arch Ophthalmol* 1984; 102:520-6.
105. Rand LI, Krolewski AS, Aiello LM, et al. Multiple factors in the prediction of risk of proliferative diabetic retinopathy. *N Engl J Med* 1985; 313:1433-8.
106. Klein R, Klein BE, Moss SE, et al. Glycosylated hemoglobin predicts the incidence and progression of diabetic retinopathy. *JAMA* 1988; 260:2864-71.
107. Klein R, Klein BE, Moss SE, DeMets DL. Blood pressure and hypertension in diabetes. *Am J Epidemiol* 1985; 122:75-89.
108. Tight blood pressure control and risk of macrovascular and microvascular complications in type 2 diabetes. UKPDS 38. UK Prospective Diabetes Study Group. *BMJ* 1998;317:703-13/

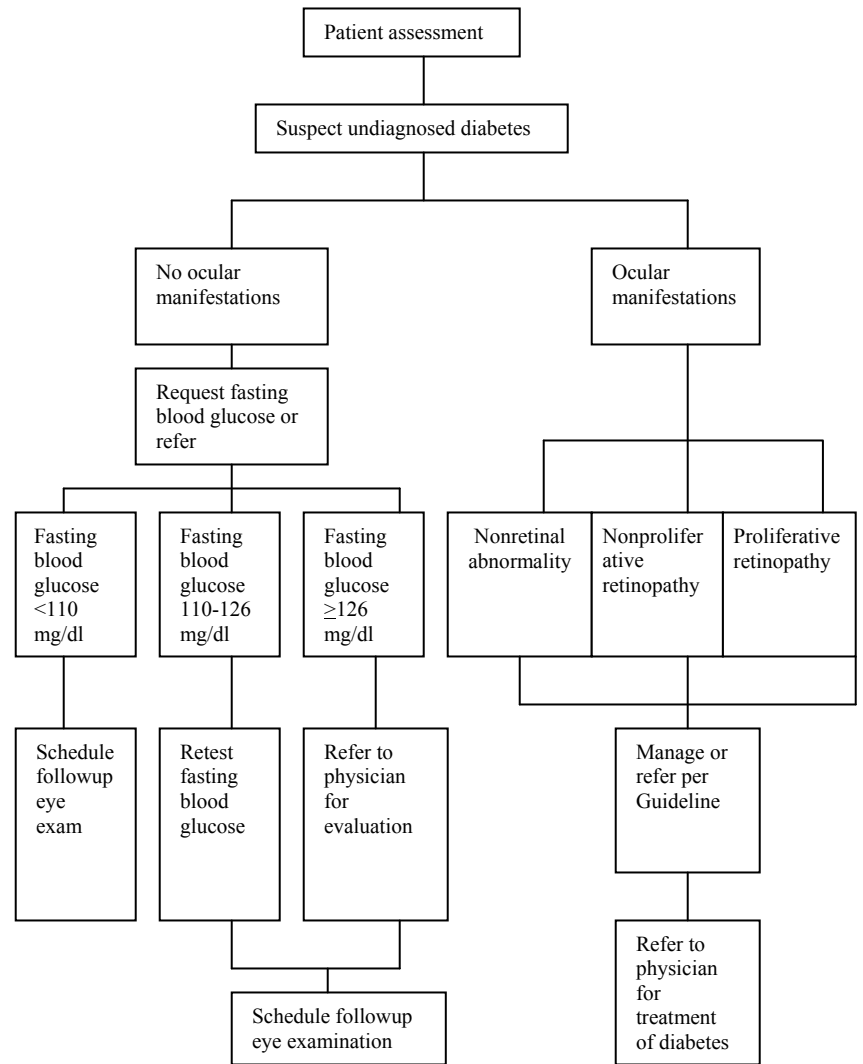
109. Browning DJ, Glassman AR, Aiello LP, Bressler NM, et al. and the Diabetic Retinopathy Clinical Research Network Study Group. Optical coherence tomography measurements and analysis methods in optical coherence tomography studies of diabetic macular edema. *Ophthalmology* 2008 Aug;115:1366-1371.
110. Glassman AR, Beck RW, Browning DJ, Danis RP, Kollman, C for the Diabetic Retinopathy Clinical Research Network Study Group. Comparison of optical coherence tomography retinal thickness measurements in diabetic macular edema with and without reading center manual grading from a clinical trials perspective. *Invest Ophthalmol Vis Sci*. 2009 Feb;50:560-566.
111. Diabetic Retinopathy Clinical Research Network. DRCR.net studies. <http://public.drcre.net/DRCRnetstudies/StudiesIndex.html> (accessed 10 Feb 2009).
112. Scott IU, Bressler NM, Bressler SB, Browning DJ, et al., and the Diabetic Retinopathy Clinical Research Network Study Group. Agreement between clinician and reading center gradings of diabetic retinopathy severity level at baseline in a phase 2 study of intravitreal bevacizumab for diabetic macular edema. *Retina*. 2008 Jan;28:36-40.
113. Diabetic Retinopathy Clinical Research Network. Randomized trial comparing intravitreal triamcinolone acetonide and focal/grid photocoagulation for diabetic macular edema. *Ophthalmology* 2008 Sep;115(9):1447-1459.
114. Diabetic Retinopathy Clinical Research Network. A randomized trial comparing intravitreal triamcinolone acetonide and focal/grid photocoagulation for diabetic macular edema. *Ophthalmology* 2008;115:1447-1459.
115. Cavallerano JD. Non-retinal ocular complications of diabetes mellitus. *J Am Optom Assoc* 1990; 61:533-43.

116. Ferris FL III. Early photocoagulation in patients with either type I or type II diabetes. *Trans Am Ophthalmol Soc* 1996; 94:505-37.
117. Aiello LM, Cavallerano JD. Indications for laser treatment of diabetic retinopathy. *Curr Opin Endocrinol Diabetes* 1997; 4:56-62.
118. Waite JH, Beetham WP. The visual mechanism in diabetes mellitus: a comparative study of 2002 diabetics and 457 non-diabetics for control. *N Engl J Med* 1935; 212:367-79.
119. Klein R, Klein BE, Moss SE, Cruickshanks KJ. Relationship of hyperglycemia to the long-term incidence and progression of diabetic retinopathy. *Arch Intern Med* 1994; 154:2169-78.
120. Cooppan R. Diabetes in the elderly: implications of the Diabetes Control and Complications Trial. *Compr Ther* 1996; 22(5):286-90.
121. Lewis EJ, Hunsicker LG, Bain RP, Rohde RD. The effect of angiotensin-converting-enzyme inhibition on diabetic nephropathy. *N Engl J Med* 1993; 329:1456-62.
122. Ravid M, Lang R, Rachmani R, Lishner M. Long-term renoprotective effect of angiotensin-converting-enzyme inhibition in non-insulin dependent diabetes mellitus. A 7-year follow-up study. *Arch Intern Med* 1996; 156:286-9.
123. Bresnick GH, Groo A, Palta M, Korth K. Urinary glucose testing inaccuracies among diabetic patients. Effect of acquired color vision deficiency caused by diabetic retinopathy. *Arch Ophthalmol* 1984; 102:1489-96.
124. Oehler Giarratana J. Meeting the psychosocial and rehabilitative needs of the visually impaired diabetic. *J Vis Impair Blind* 1978; 72:358-61.

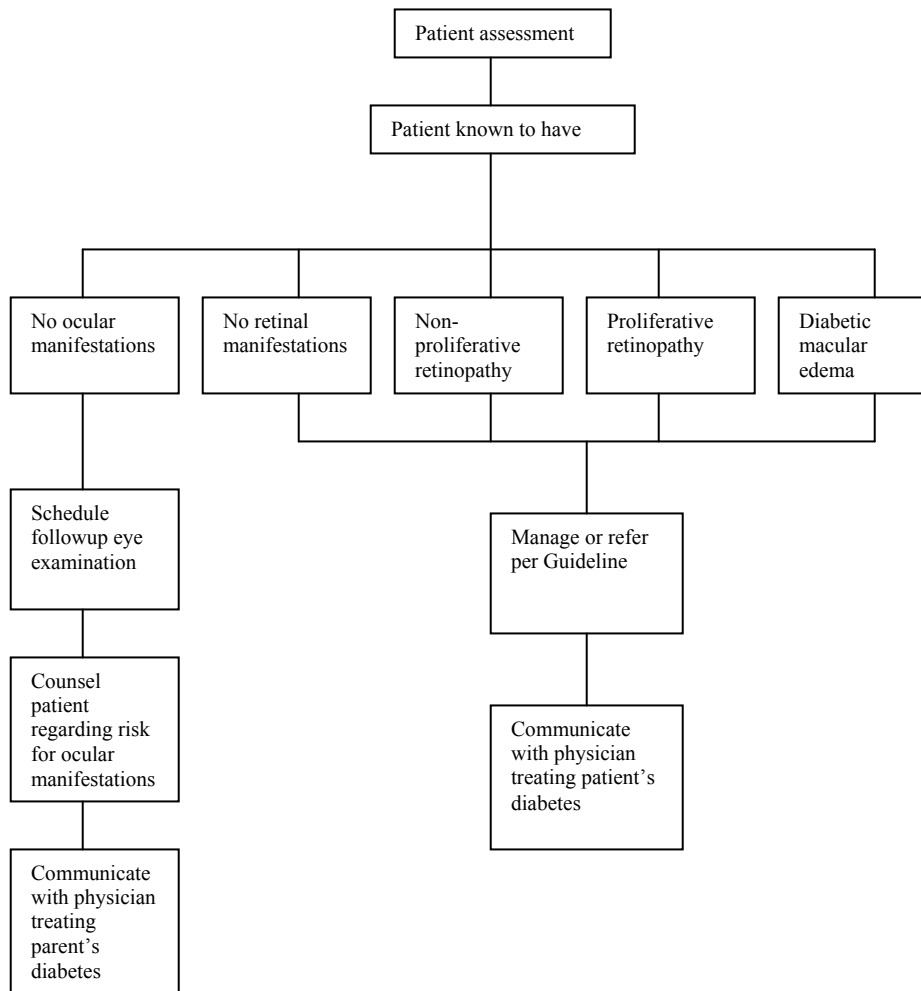
- 125. Shindell S. Psychological sequelae to diabetic retinopathy. J Am Optom Assoc 1988; 59:870-4.
- 126. Wulsin LR, Jacobson AM, Rand LI. Psychosocial aspects of diabetic retinopathy. Diabetes Care 1987; 10:367-73.
- 127. Aiello LP, Gardner TW, King GL, et al. Diabetic retinopathy. Diabetes Care 1998; 21:143-56.

IV. APPENDIX

**Figure 1**  
**Optometric Management of the Patient**  
**With Undiagnosed Diabetes: A Brief Flowchart**



**Figure 2**  
**Optometric Management of the Patient**  
**With Diagnosed Diabetes Mellitus: A Brief Flowchart**



**Figure 3**  
**Frequency and Composition of Evaluation and Management**  
**Visits for Retinal Complications of Diabetes Mellitus**

Severity of Condition	Natural Course Rate of Progression to		Frequency of Followup	Composition of Followup Evaluations†	
	PDR (1 year)	HRC (5 years)		Fundus Photography	Fluorescein Angiography
Mild NPDR	5%	15%			
No macular edema			12 mos	No	No
Macular edema			4-6 mos	Yes	Occ.
CSME			2-4 mos	Yes	Yes
Moderate NPDR	12-27%	33%			
No macular edema			6-8 mos	Yes	No
Macular edema (not CSME)			4-6 mos	Yes	Occ.
CSME			2-4 mos	Yes	Yes
Severe NPDR	52%	60-75%			
No macular edema			3-4 mos	Yes	No
Macular edema (not CSME)			2-3 mos	Yes	Occ.
CSME			2-3 mos	Yes	Yes
Non-high-risk PDR		75%			
No macular edema			2-3 mos	Yes	No
Macular edema			2-3 mos	Yes	Occ.
CSME			2-3 mos	Yes	Yes
High-risk PDR					
No macular edema			2-3 mos	Yes	No
Macular edema			1-2 mos	Yes	Yes
CSME			1-2 mos	Yes	Yes

Figure 3 (continued)

Management Plan*		
Referral for Consultation and/or Treatment	Scatter Laser Treatment	Focal Laser Treatment
Communicate with patient's physician Obtain retinal consult in 2-4 wks. Obtain retinal consult in 2-4 wks.	No No No	No No Yes
Communicate with patient's physician Obtain retinal consult in 2-4 wks.  Obtain retinal consult in 2-4 wks.	No No No	No No Yes
Obtain retinal consult in 2-4 wks. Obtain retinal consult in 2-4 wks.	Rarely** Occ. after focal**	No Occ.
Obtain retinal consult in 2-4 wks.	Occ. after focal**	Yes
Obtain retinal consult in 2-4 wks. Obtain retinal consult in 2-4 wks. Obtain retinal consult in 2-4 wks.	Occ.*** Occ. after focal*** Occ. after focal***	No Occ. Yes
Obtain retinal consult in 24-48 hrs. or as soon as possible Obtain retinal consult in 24-48 hrs. or as soon as possible Obtain retinal consult in 24-48 hrs. or as soon as possible	Yes Yes Yes	No Usually Yes

†Other imaging modalities such as optical coherence tomography (OCT) and ocular ultrasonography (U) may be indicated in the presence of diabetic macular edema, vitreous hemorrhage, media opacity, vitreo-retinal traction, and other complications.

\*Patient education and written communication with patient's primary care physician are integral to management of DR.

\*\*Consider scatter laser treatment (PRP), especially if every severe NPDR (see levels of DR), significant medical complication, or type 2 DM.

\*\*\*Consider scatter laser treatment (PRP), especially if moderate PDR (see levels of DR), significant medical complication, or type 2 DM.

HRC = High risk category; Occ. = Occasionally

Table copyright L.M. Aiello, M.D. Used with permission.

Figure 4

**ICD-9-CM Classification of Ocular Complications of Diabetes Mellitus**

Diabetes mellitus 250

*Excludes: gestational diabetes (648.8)  
hyperglycemia NOS (790.6)  
neonatal diabetes mellitus (775.1)  
nonclinical diabetes (790.2)*

*The following fifth-digit subclassification is for use with category 250:*

- 0 type II [non-insulin dependent type][NIDDM type][adult-onset type] or unspecified type, not stated as uncontrolled  
*Fifth-digit 0 is for use for type 2, adult-onset, diabetic patients, even if the patient requires insulin*
- 1 type I [insulin dependent type][IDDM type][juvenile type], not stated as uncontrolled
- 2 type II, [non-insulin dependent type][NIDDM type][adult-onset type] or unspecified type, uncontrolled  
*Fifth-digit 2 is for use for type II, adult-onset, diabetic patients, even if the patient requires insulin*
- 3 type I [insulin dependent type][IDDM][juvenile type], uncontrolled

67 Appendix

Diabetes with ophthalmic manifestations	250.5
Use additional code, if desired, to identify manifestation, as: diabetic:	
blindness (369.00-369.9)	
cataract (366.41)	
glaucoma (365.44)	
retinal edema (362.83)	
retinopathy (362.01-362.02)	
Diabetic retinopathy	362.0
<i>Code first diabetes (250.5)</i>	
Background diabetic retinopathy	362.01
Diabetic macular edema	
Diabetic retinal edema	
Diabetic retinal microaneurysms	
Diabetic retinopathy NOS	
Proliferative diabetic retinopathy	362.02
Retinal microaneurysms NOS	362.14
Retinal telangiectasia	362.15
Retinal neovascularization NOS	362.16
Neovascularization	
choroidal	
subretinal	
Other intraretinal microvascular abnormalities	362.17
Retinal varices	
Retinal hemorrhage	362.81
Hemorrhage:	
preretinal	
retinal (deep) (superficial)	
subretinal	

68 Diabetes Mellitus

Retinal exudates and deposits	362.82
Retinal edema	362.83
Retinal:	
cotton wool spots	
edema (localized) (macular) (peripheral)	
Retinal ischemia	362.84
Rubeosis iridis	364.42
Neovascularization of iris or ciliary body	
Glaucoma associated with systemic syndromes	365.44
<i>Code first associated disease</i>	
Glaucoma associated with vascular disorders	365.63
Use additional code for associated disorder	
Diabetic cataract	366.41
<i>Code first diabetes (250.5)</i>	
Transient refractive change	367.81
Diplopia	368.2
Double vision	
Visual field defect, unspecified	368.40
Tritan defect	368.53
Tritanomaly	
Tritanopia	
Recurrent erosion of cornea	371.42
Tear film insufficiency, unspecified	375.15
Dry eye syndrome	
Ischemic optic neuropathy	377.41
Vitreous hemorrhage	379.23



**Abbreviations of Commonly Used Terms**

ACE	-	Angiotensin-converting enzyme
ADA	-	American Diabetes Association
BMI	-	Body mass index
CSME	-	Clinically significant macular edema
DA	-	Disc area
DCCT	-	Diabetes Control and Complications Trial
DD	-	Disc diameter
DM	-	Diabetes mellitus
DNA	-	Deoxyribonucleic acid
DR	-	Diabetic retinopathy
DRCR	-	The Diabetic Retinopathy Clinical Research Network (DRCR.net)
DRS	-	Diabetic Retinopathy Study
DRVS	-	Diabetic Retinopathy Vitrectomy Study
ETDRS	-	Early Treatment Diabetic Retinopathy Study
FA	-	Fluorescein angiography
FDA	-	Food and Drug Administration
FPD	-	Fibrous proliferations on or within 1 DD of disc margin
FPE	-	Fibrous proliferations elsewhere, not FPD
FPG	-	Fasting plasma glucose
GAD65	-	Glutamic acid decarboxylase
GDM	-	Gestational diabetes mellitus
HbA1C	-	Glycosylated hemoglobin
HDL	-	High-density lipoprotein(s)
HLA	-	Human leukocyte antigen(s)

H/Ma	-	Hemorrhage(s) and/or microaneurysm(s)
IAs	-	Insulin autoantibodies
ICAs	-	Islet cell antibodies
IDDM	-	Insulin dependent diabetes mellitus
IFG	-	Impaired fasting glucose
IGT	-	Impaired glucose tolerance
IRMA	-	Intraretinal microvascular abnormality
LDL	-	Low-density lipoproteins
Ma	-	Microaneurysms
ME	-	Macular edema
MODY	-	Maturity-onset diabetes of the young
NIDDM	-	Non-insulin dependent diabetes mellitus
NPDR	-	Nonproliferative diabetic retinopathy
NVD	-	New vessels on or within 1 DD of disc margin
NVE	-	New vessels elsewhere in the retina outside of disc and 1 DD from disc margin
NVI	-	New vessels on the iris; rubeosis iridis
OCT	-	Optical coherence tomography
OGTT	-	Oral glucose tolerance test
PAI-1	-	Plasminogen activator inhibitor
PDR	-	Proliferative diabetic retinopathy
PRH	-	Preretinal hemorrhage
UKPDS	-	United Kingdom Prospective Diabetes Study
US	-	Ultrasound
VB	-	Venous beading
VCAB	-	Venous Caliber Abnormalities

- VH - Vitreous hemorrhage  
WHO - World Health Organization

**Glossary**

**Diabetes mellitus (DM)** A group of metabolic disorders characterized by hyperglycemia resulting from defects in insulin secretion, insulin action, or both.

- **Type 1 diabetes** The result of cell-mediated autoimmune destruction of the beta cells of the pancreas, formerly referred to as insulin-dependent diabetes mellitus (IDDM).
- **Type 2 diabetes** A disease in which individuals can produce insulin but have cellular resistance to it, formerly referred to as non-insulin-dependent diabetes mellitus (NIDDM)

**Diabetic cataract** A rapidly forming, sometimes reversible, bilateral cataract associated with diabetes mellitus.

**Diabetic papillopathy** A noninflammatory edema of the optic nerve head associated with diabetes mellitus.

**High-risk proliferative diabetic retinopathy** New vessels on or within 1 disc diameter of the optic nerve head greater than approximately one-fourth to one-third of the disc, or new vessels on or within 1 disc diameter of the optic nerve head less than one-fourth to one-third of the disc area when accompanied by vitreous and/or preretinal hemorrhage, or new vessels elsewhere in the retina greater than one-half the size of the disc area.

**Intraretinal hemorrhage** A radially striated hemorrhage in the inner layers of the retina, especially in the nerve fiber layer (flame-shaped hemorrhage).

**Intraretinal microvascular abnormality (IRMA)** An abnormality that represents either new vessel growth within the retina or pre-existing vessels with endothelial cell proliferation.



**Macular edema (ME)** Collection of intraretinal fluid in the macular portion of the retina, with or without lipid exudates, and with or without cystoid changes.

**Clinically significant macular edema (CSME)** The case when there is retinal thickening at or within 500 microns of the center of the macular and/or hard exudates within 500 microns of the center of the macula associated with retinal thickening of the adjacent area of the retina and/or a zone or zones of retinal thickening 1 disc area in size, any part of which is within 1 disc diameter of the center of the macula.

**Microaneurysm (Ma)** As to the eye, a focal retinal capillary dilation.

**Neovascularization** Growth of abnormal new blood vessels.

**Papilledema** Noninflammatory edema of the optic nerve head from various causes, such as increased intracranial pressure, orbital tumor, or blood dyscrasias.

**Proliferative diabetic retinopathy (PDR)** A type of retinopathy associated with diabetes mellitus, characterized by proliferation of connective tissue and the formation of new blood vessels in the retina, and by hemorrhages into the vitreous.

**Retinal hypoxia** A deficiency of oxygen supply to the retinal tissue.

**Rubeosis iridis** Noninflammatory neovascularization of the iris occurring in diabetes mellitus, characterized by numerous, small intertwining blood vessels which anastomose near the sphincter region to give the appearance of a reddish ring near the border of the pupil. The vessels may extend from the root of the iris to the filtration angle to cause peripheral vascular synechiae and secondary glaucoma.

**Venous beading (VB)** A fragmented appearance of the bloodstream in the retinal veins subsequent to retinal artery occlusion.

**Sources:**

Coles WH. Ophthalmology: a diagnostic text. Baltimore: Williams & Wilkins, 1989.

Hofstetter HW, Griffin JR, Berman MS, Everson RW. Dictionary of visual science and related clinical terms, 5th ed. Boston: Butterworth-Heinemann, 2000.

Rhee DJ, Pyfer MF, eds. The Wills eye manual: office and emergency room diagnosis and treatment of eye disease, 3rd ed. Philadelphia: Lippincott Williams & Wilkins, 1999: 452-7.

Stedman's medical dictionary, 27th ed. Baltimore: Williams & Wilkins, 2000.

